

GUIDELINES AND STANDARDS

Guidelines for Performing a Comprehensive Transthoracic Echocardiographic Examination in Adults: Recommendations from the American Society of Echocardiography

Carol Mitchell, PhD, ACS, RDMS, RDCS, RVT, RT(R), FASE, Co-Chair, Peter S. Rahko, MD, FASE, Co-Chair, Lori A. Blauwet, MD, FASE, Barry Canaday, RN, MS, RDCS, RCS, FASE, Joshua A. Finstuen, MA, RT(R), RDCS, FASE, Michael C. Foster, BA, RCS, RCCS, RDCS, FASE, Kenneth Horton, ACS, RCS, FASE, Kofo O. Ogunyankin, MD, FASE, Richard A. Palma, BS, RDCS, RCS, ACS, FASE, and Eric J. Velazquez, MD, FASE, *Madison, Wisconsin; Rochester, Minnesota; Klamath Falls, Oregon; Durham, North Carolina; Salt Lake City, Utah; Ikoyi, Lagos, Nigeria; and Hartford, Connecticut*

This document is endorsed by the following American Society of Echocardiography International Alliance Partners: Argentine Federation of Cardiology, Argentine Society of Cardiology, ASEAN Society of Echocardiography, Australasian Sonographers Association, British Society of Echocardiography, Canadian Society of Echocardiography, Chinese Society of Echocardiography, Department of Cardiovascular Imaging of the Brazilian Society of Cardiology, Indian Academy of Echocardiography, Indian Association of Cardiovascular Thoracic Anaesthesiologists, Indonesian Society of Echocardiography, InterAmerican Association of Echocardiography, Iranian Society of Echocardiography, Israel Work Group on Echocardiography, Italian Association of Cardiothoracic Anaesthesiologists, Japanese Society of Echocardiography, Korean Society of Echocardiography, National Society of Echocardiography of Mexico, Philippine Society of Echocardiography, Saudi Arabian Society of Echocardiography, Thai Society of Echocardiography, Vietnamese Society of Echocardiography.

Keywords: Transthoracic echocardiography, Doppler echocardiography, Color Doppler echocardiography, Comprehensive examination, Protocol

TABLE OF CONTENTS

I. Introduction	3
II. Nomenclature	4
A. Image Acquisition Windows	4
B. Scanning Maneuvers	5
C. Measurement Techniques	5
III. Instrumentation	5

A. Two-Dimensional Imaging	5
1. Grayscale Maps	5
2. B-mode Colorization	6
3. Dynamic Range	6
4. Transmit Frequency	6
5. Harmonic Imaging	7
6. Sector Size and Depth	8
7. Transducer Beam Focus	8
8. Overall Gain and Time-Gain Compensation	8

From the University of Wisconsin School of Medicine and Public Health, Madison, Wisconsin (C.M., P.S.R.); the Mayo Clinic, Rochester, Minnesota (L.A.B., J.A.F.); the Oregon Institute of Technology, Klamath Falls, Oregon (B.C.); Duke University Medical Center, Durham, North Carolina (M.C.F., E.J.V.); Intermountain Heart Institute, Intermountain Medical Center, Salt Lake City, Utah (K.H.); First Cardiology Consultants Hospital, Ikoyi, Lagos, Nigeria (K.O.O.); and St. Francis Hospital and Medical Center, Hartford, Connecticut (R.A.P.).

This document is endorsed by the following American Society of Echocardiography International Alliance Partners: the Cardiovascular Imaging Department of the Brazilian Society of Cardiology, the Chinese Society of Echocardiography, the Indian Academy of Echocardiography, the Japanese Society of Echocardiography, the InterAmerican Association of Echocardiography, the Italian Association of Cardiothoracic Anaesthesiologists.

The following authors reported no actual or potential conflicts of interest in relation to this document: Peter S. Rahko, MD, FASE, Lori A. Blauwet, MD, FASE, Barry Canaday, RN, MS, RDCS, RCS, FASE, Joshua A. Finstuen, MA, RT(R), RDCS, FASE, Michael C. Foster, BA, RCS, RCCS, RDCS, FASE, Kenneth Horton, ACS, RCS, FASE, Kofo O. Ogunyankin, MD, FASE. The following authors reported relationships with one or more commercial interests: Carol Mitchell, PhD, ACS, RDMS, RDCS, RVT, RT(R), FASE, authored a textbook for Davies Publishing Inc., and authorship with royalties for Elsevier and Wolters-Kluwer. Richard A. Palma, BS,

RDCS, RCS, ACS, FASE, has served on the speakers bureau for Lantheus Medical Imaging and as a faculty speaker for Gulf Coast Ultrasound. Eric J. Velazquez, MD, FASE, received cardiovascular research grants from the National Institutes of Health/National Heart, Lung, and Blood Institute, Alnylam Pharmaceuticals, Amgen, General Electric, Novartis Pharmaceutical, and Pfizer and has served as a consultant for ABIOMED, Amgen, Merck, New Century Health, Novartis Pharmaceutical, and Philips Ultrasound.

* Reprint requests: American Society of Echocardiography, Meridian Corporate Center, 2530 Meridian Parkway, Suite 450, Durham, NC 27713 (E-mail: ase@asecho.org).

Attention ASE Members:

Visit www.aseuniversity.org to earn free continuing medical education credit through an online activity related to this article. Certificates are available for immediate access upon successful completion of the activity. Nonmembers will need to join the ASE to access this great member benefit!

0894-7317/\$36.00

Copyright 2018 by the American Society of Echocardiography.

<https://doi.org/10.1016/j.echo.2018.06.004>

Abbreviations

2D = Two-dimensional
3C = Three-chamber (apical long axis)
3D = Three-dimensional
4C = Four-chamber
5C = Five-chamber
A2C = Apical two-chamber
A4C = Apical four-chamber
Abd Ao = Abdominal aorta
ALPap = Anterolateral papillary muscle
AMVL = Anterior leaflet mitral valve
Ao = Aorta
AR = Aortic valve regurgitation
Asc Ao = Ascending aorta
ASE = American Society of Echocardiography
AV = Aortic valve
CDI = Color Doppler imaging
CS = Coronary sinus
CW = Continuous-wave
Desc Ao = Descending aorta
DTI = Doppler tissue imaging
HPRF = High-pulse repetition frequency
Hvns = Hepatic vein
IAS = Interatrial septum
Innom a = Innominate artery
IVC = Inferior vena cava
IVS = Interventricular septum
LA = Left atrial
LCC = Left coronary cusp
LCCA = Left common carotid artery
L innom vn = Left innominate vein
LSA = Left subclavian artery
LV = Left ventricular
LVIDd = Left ventricular internal dimension diastole
LVIDs = Left ventricular internal dimension systole
LVOT = Left ventricular outflow tract
LVPW = Left ventricle posterior wall
MPA = Main pulmonary artery
MR = Mitral valve regurgitation
MS = Mitral stenosis
MV = Mitral valve

NCC = Noncoronary cusp
PA = Pulmonary artery
PFO = Patent foramen ovale
PLAX = Parasternal long-axis
PMPap = Posteromedial papillary muscle
PMVL = Posterior leaflet mitral valve
PR = Pulmonic valve regurgitation
PRF = Pulse repetition frequency
PSAX = Parasternal short-axis
Pulvn = Pulmonary vein
PV = Pulmonic valve
PW = Pulsed-wave
RA = Right atrium
RCA = Right coronary artery
RCC = Right coronary cusp
R innom vn = Right innominate vein
ROI = Region of interest
RPS = Right parasternal
RV = Right ventricular
RVIDd = Right ventricular internal dimension diastole
RVOT = Right ventricular outflow tract
SC = Subcostal
SoVAo = Sinus of Valsalva
SSN = Suprasternal notch
STJ = Sinotubular junction
SVC = Superior vena cava
TAPSE = Tricuspid annular plane systolic excursion
TGC = Time-gain compensation
TR = Tricuspid valve regurgitation
TTE = Transthoracic echocardiographic
TV = Tricuspid valve
UEA = Ultrasound enhancement agent
VTI = Velocity-time integral

9. Zoom/Magnification 8
10. Frame Rate 8
- B. Spectral Doppler 8
 1. Velocity Scale 8
 2. Sweep Speed 8
 3. Sample Volume Size 10
 4. Wall Filters and Gain 10
 5. Display Settings 12
 6. Pulsed-Wave Doppler, High-Pulse Repetition Frequency Doppler, and CW Doppler 12
 7. Doppler Tissue Imaging 15
- C. Color Doppler Imaging 17

1. ROI and 2D Sector Size 17
2. Color Gain 17
3. Color Maps 17
4. Color Doppler Velocity Scale 17
- D. M Mode 18
 1. Color M Mode 18
 2. Steerable M Mode 18
- E. Electrocardiographic Setup 18
- IV. Two-Dimensional Imaging Protocol 23
 - A. PLAX View 23
 1. PLAX View: Left Ventricle 25
 2. Right Ventricular Outflow Tract View 25
 3. Right Ventricular Inflow View 25
 - B. PSAX Views 25
 - C. Apical Views 26
 1. A4C View 26
 2. Right Ventricle–Focused View 26
 3. Apical Five-Chamber View 26
 4. CS View 26
 5. Two-Chamber View 30
 6. Apical Long-Axis View (Three-Chamber View) 30
 7. A4C and A2C Views Demonstrating the Atria and Pulvns 30
 - D. SC Window and Views 31
 1. SC Four-Chamber View 31
 2. SC Short-Axis View 31
 - E. SSN Long-Axis View 31
- V. Two-Dimensional Measurements 31
 - A. PLAX View 31
 1. Left Ventricle 31
 2. Proximal RVOT 31
 3. Anterior to Posterior LA Measurements 31
 4. LVOT and Aortic Annulus 31
 5. Asc Ao 32
 - B. PSAX View 33
 1. RVOT 33
 2. PA 33
 - C. Apical Views 33
 1. LV Volume 33
 - a. Biplane Disk Summation 33
 - b. Three-Dimensional LV Volume 33
 2. LA Volume 33
 3. RV Linear Dimensions 33
 4. RV Area 33
 5. Right Atrial Volume 33
 - D. SC Views 37
 1. IVC 37
- VI. M-Mode Measurements 37
 - A. TAPSE 37
 - B. IVC 37
 - C. AV 37
- VII. CDI 37
 - A. RVOT, Pulmonary Valve, and PA 41
 - B. RV Inflow and TV 41
 - C. LV Inflow and MV 41
 - D. LVOT and AV 42
 - E. Aortic Arch 42
 - F. Pulvns 42
 - G. Hvns 42
 - H. IVC 42
 - I. Atrial Septum 42
- VIII. Spectral Doppler Imaging Measurements 42
 - A. RVOT and Pulmonary Valve 43
 - B. TV 43
 - C. MV 43
 - D. LVOT and AV 43
 - E. Aortic Arch and Desc Ao 46
 - F. Hvns 46
 - G. Pulvns 46
 - H. Tissue Doppler of the Mitral and Tricuspid Annuli 48
- IX. Additional Techniques 48
 - A. Agitated-Saline Imaging 48
 - B. UEA Imaging 49
 1. Indications 49
 2. Instrumentation and Administration 54
 3. Image Acquisition 54
 - C. Strain Imaging 54
 - D. Three-Dimensional Evaluation of LV Size and Systolic Function 55
- X. The Integrated Complete Transthoracic Examination 55
- XI. The Limited Transthoracic Examination 55
 - A. Pericardial Effusion 55
 - B. LV Function 55
 - C. Limited Right Ventricle and Pulmonary Hypertension 55
- XII. References 56
- XIII. Appendix: Additional Alternative Views 59
 - A. PSAX Coronary Artery View 59
 - B. RVA2C View 59
 - C. SC SVC (Bicaval) View 59
 - D. SC Abdominal Aorta 59
 - E. Right Lateral Imaging of the IVC 59
 - F. SC Short-Axis IVC 59
 - G. SC Focused Interatrial Septum 59
 - H. SC Short-Axis RVOT View 59
 - I. SC Short-Axis Sweep from the Level of the Great Arteries through the Apex of the Heart 59
 - J. Right Parasternal View of the Aorta 59
 - K. SSN Innominate Veins 64
 - L. SSN Short-Axis LA and Pulvn View (“Crab View”) 64
 - M. Color M-Mode Flow Propagation 64

I. INTRODUCTION

Since the first report of the use of ultrasound for cardiovascular diagnosis by Edler and Hertz¹ in 1954, echocardiography has expanded exponentially over the ensuing decades. The history of echocardiography is one of continuous innovation. With each discovery of new technology, the echocardiographic examination has progressively become longer, more comprehensive, and integrated with more diverse technology. In some circumstances, refined technology has completely replaced old methods. In other circumstances, new technology is incorporated to enhance existing capabilities.

Several professional organizations, including the American Society of Echocardiography (ASE), have put considerable effort into the development of a wide array of comprehensive guidelines, typically focusing on the use of echocardiography for specific clinical purposes. Other guidelines have focused on specific technique-based recommendations for such aspects of the examination as chamber quantification or diastolic performance.^{2,3} Accrediting agencies such as the Intersocietal Accreditation Commission have established standards for components of the echocardiographic examination.⁴

The ASE established standards for the two-dimensional (2D) transthoracic echocardiographic (TTE) examination in 1980⁵ and updated recommended components of the examination in 2011.⁶ Recently the British Society of Echocardiography updated a minimum data set for standard adult transthoracic echocardiography,⁷ and the Swiss Society of Cardiology⁸ has established standards for the performance of an echocardiographic examination by a cardiologist.

The ASE has convened this writing group to establish new guidelines for the performance of a comprehensive TTE examination. Our purposes are to (1) establish the content of a comprehensive TTE examination, (2) provide recommendations for technical performance and

appropriate use of instrumentation during the examination, (3) provide guidance for the integration of the various ultrasound-based imaging modalities into the comprehensive examination, and (4) describe best practices for the measurement and display of the data generated by the comprehensive examination. It should be noted that pathology-specific measurements are beyond the scope of this document.

This document is divided into the following sections:

- I. Introduction
- II. Nomenclature

This section will define standard views and scanning maneuvers that are used in this text.

- III. Instrumentation

This section provides recommendations and guidance for the use of modern ultrasound equipment to optimally display all modalities of the transthoracic examination.

- IV. Two-Dimensional Imaging

This section defines the writing committee's recommendations for the 2D-based views to be included in a comprehensive examination.

- V. Two-Dimensional Measurements

This section provides guidance on the standard measurements that should be obtained as part of the comprehensive TTE examination.

- VI. M-Mode Measurements

This section provides guidance on selected M-mode measurements.

- VII. Color Doppler Imaging

This section defines the basic imaging windows, display, and measurements for color Doppler imaging (CDI) to be integrated into the comprehensive transthoracic examination. Similarly, display of color Doppler flow interrogation for valves, vessels, and chambers is defined.

- VIII. Spectral Doppler Imaging

This section defines the basic imaging windows, display, and measurements for spectral Doppler to be integrated into the comprehensive transthoracic examination. Similarly, display and measurement of spectral Doppler flow interrogation for valves, vessels, and chambers are defined.

- IX. Additional Techniques

The guideline makes recommendations on the use of agitated saline as well as ultrasound enhancement agents (UEAs) for improvement of endocardial border detection. The committee also recommends, when practicable, use of longitudinal strain imaging and three-dimensional (3D) evaluation of ventricular size and function as part of the standard examination.

- X. Examination Sequence

The integrated complete transthoracic examination is enumerated in a recommended sequence of performance. We also make recommendations for selective use of a limited transthoracic examination.

II. NOMENCLATURE

A. Image Acquisition Windows

The following nomenclature defines the imaging planes, views, and scanning maneuvers. Transducer movements will describe motions directed anterior, posterior, superior, inferior, lateral and medial (Figure 1). All ul-

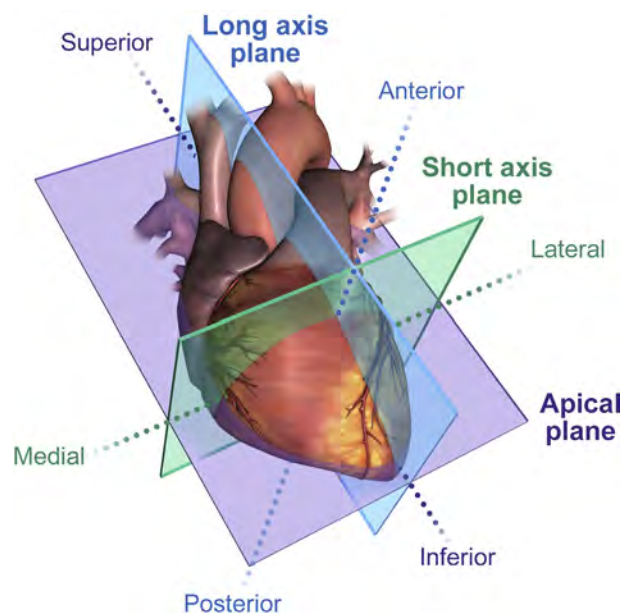


Figure 1 Scanning planes of the heart. The long-axis plane corresponds to images acquired in the PLAX views. The short-axis plane corresponds to images acquired in the PSAX views. The apical plane corresponds to images acquired from the apical window.

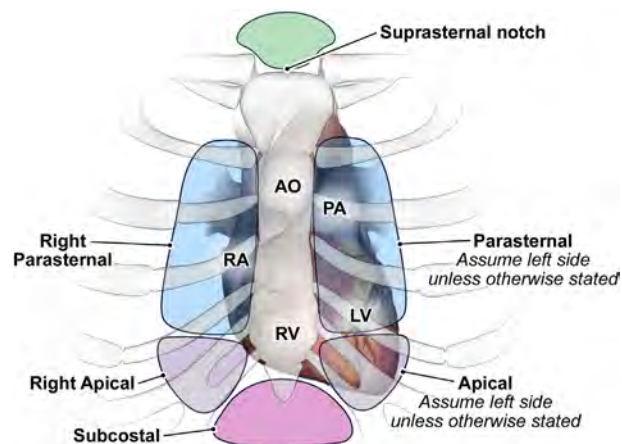


Figure 2 Echocardiographic windows to obtain images.

trasound system transducers have an orientation index marker. Each view described in this text will provide orientation information on the basis of positioning of the index marker. The imaging windows described are the parasternal, apical, subcostal (SC), and suprasternal notch (SSN) (Figure 2). The patient is positioned in the left lateral decubitus position (as long as the patient is able to move) for image acquisition in the left parasternal and apical windows. The parasternal long-axis (PLAX) view is located on the left side of the sternum and will provide imaging planes of the long axis of the heart with the index marker pointed toward the patient's right shoulder. The initial parasternal short-axis (PSAX) view is located in the same location as the PLAX view, but the index marker is pointed toward the patient's left shoulder. This view provides images of the heart in an axial plane. The apical window is located below the left breast tissue, where one can feel the apical impulse. In the apical window the index marker is initially placed in the 4 to 5 o'clock position to demonstrate the apical four-chamber (A4C) view. The SC window is located on

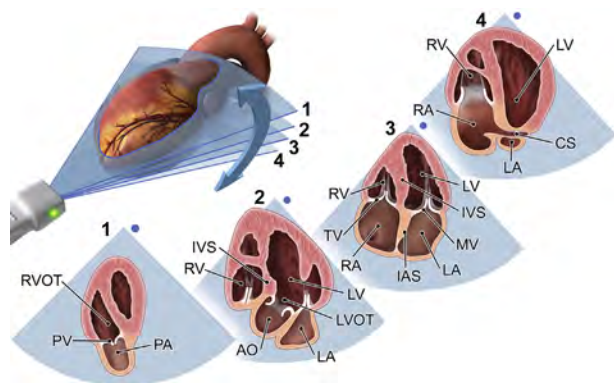


Figure 3 Tilting maneuver of the transducer. The *blue dot* represents the index orientation marker.

the anterior surface of the body, just below the sternum. Image acquisition for this window is performed with the patient in the supine position. The initial view from this window is the SC four-chamber view, which is obtained with the index marker directed toward the patient's left side at the 3 o'clock position.^{2,9-12} The SSN window is located just superior to the manubrium of the sternum. Images are obtained from this window with the patient in the supine position. The initial view demonstrated is the long axis of the aortic arch. The transducer orientation index marker is initially directed toward the left shoulder, and the face of the transducer is directed inferior so that the transducer is almost parallel with the neck. Small movements of rocking and angling may be used to demonstrate the best view of the aortic arch.

B. Scanning Maneuvers

The terms *tilt*, *sweep*, *rotate*, *slide*, *rock*, and *angle* will be used to define transducer movements. The term *tilt* refers to a movement in which the transducer is fixed in position and the face of the transducer is moved to demonstrate other image planes in the same axis (Figure 3).¹³ *Sweep* refers to the deliberate action of capturing a long video clip of data. An example of a sweep would be recording the tilt planes of the heart from posterior to anterior in the apical window during one long video clip. The term *rotate* refers to keeping the transducer in a stationary position but turning the index marker to a new position (Figure 4).^{9,13,14} The term *slide* refers to moving the transducer over the patient's skin to a new position (Figure 5).^{9,13,14} The terms *rock* and *angle* refer to smaller movements used to optimize an image. *Rock* refers to an action of moving the transducer, staying in the same imaging plane, toward or away from the transducer orientation marker to center a structure or extend the field of view.¹³ *Rock* differs from *tilt*, in that the *rock* motion stays in the same imaging plane (Figure 6), whereas the *tilt* motion refers to motion in the same axis but different imaging planes.¹³ *Angle* refers to a motion in which the image is optimized by keeping the transducer in the same position and directing the sound beam toward a structure of interest. An example of angling is imaging of the tricuspid valve (TV) in the parasternal window, PSAX view, then moving the transducer to image the PSAX aortic valve (AV), then manipulating the transducer to demonstrate the pulmonic valve (PV) (Figure 7).¹⁴ *Angle* differs from *rock*, in that the *rock* motion is used to center a structure, whereas the *angle* maneuver is more complex, combining several small movements to optimize imaging of a structure but not necessarily centering the structure to the middle of the image display. Throughout this document the term *optimize* refers to making the appropriate transducer movements to produce the best possible image.

C. Measurement Techniques

It is recommended by the writing group that the interface between the compacted myocardium and the noncompacted myocardium (trabeculated) be used for all 2D and 3D measurements (Figure 8). The compacted myocardium is the solid, homogenous wall separate from trabeculations within the blood-filled left ventricular (LV) cavity. In instances when this interface cannot be discerned, one should measure at the blood-tissue interface.

Key Points #1

Descriptions of transducer movements to optimize the image:

Tilt: The transducer maintains the same axis orientation to the heart but moves to a different imaging plane.

Sweep: Multiple transducer movements are used to record a long video clip to show multiple anatomic structures.

Rotate: The transducer maintains a stationary position while the index marker is moved to a new position.

Slide: The transducer moves across the patient's skin to a new position.

Rock: Within the same imaging plane, the transducer changes orientation either toward or away from the orientation marker.

Angle: The transducer is kept at the same location on the chest, and the sound beam is directed to show a new structure.

III. INSTRUMENTATION

Operators performing TTE imaging are expected to be familiar with instrumentation settings and the contributions of these settings to image quality. Some features of image production are determined by design of the ultrasound system and cannot be changed by the operator. However, several instrumentation settings can be modified during image acquisition (preprocessing) or manipulated by the operator after data are collected and stored (postprocessing), and these are important for optimal image acquisition.^{10,15}

To save time for operators and improve consistency of imaging, many laboratories set up imaging "presets" on their ultrasound equipment. Presets are instrumentation settings that are optimal for imaging a particular type of patient, anatomic structure, or blood flow and should be considered starting points for image optimization.^{10,15,16} They are time saving in that they are set for a typical patient coming to the echocardiography laboratory. Presets are available for all ultrasound imaging modes, including M-mode, 2D, and all forms of Doppler imaging.^{10,16,17} The first section of the guidelines will discuss instrumentation settings controlled by the operator.

A. Two-Dimensional Imaging

1. Grayscale Maps. The amplitude of reflected ultrasound detected by the imaging system varies over several logarithmic units of signal strength, well beyond the capacity of human visual perception. Systems process the data to enhance and suppress signals, transforming raw data into useful images that display the echocardiogram in various shades of gray. High-amplitude signals are depicted as

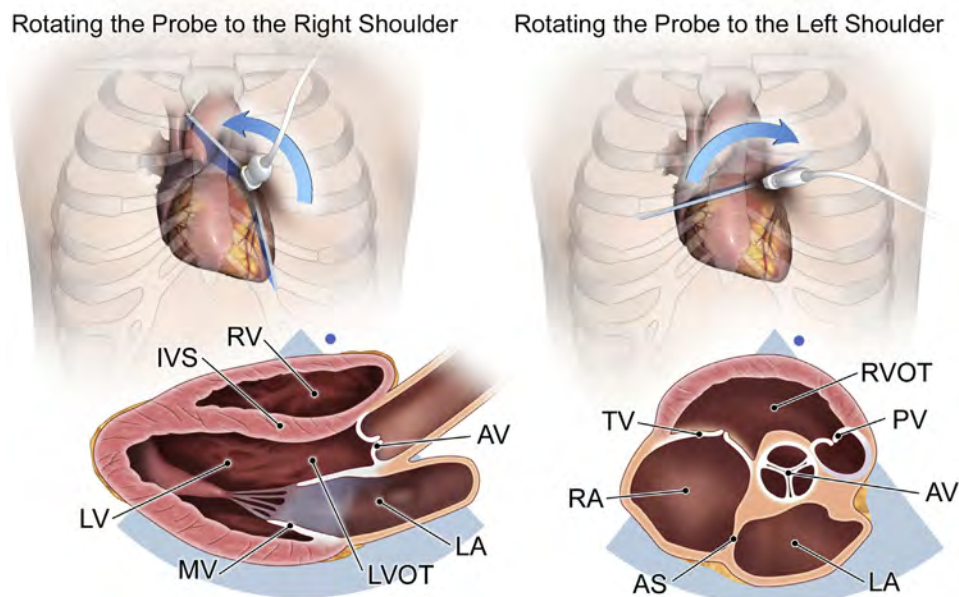


Figure 4 Rotating scanning maneuver. The *blue dot* represents the index orientation marker as it is related to the image. In the PLAX image, the *blue dot* represents the orientation index marker located on the superior aspect of the image. In the PSAX image, the *blue dot* represents the position of the orientation index marker and the lateral aspect of the image.

Sliding the Probe

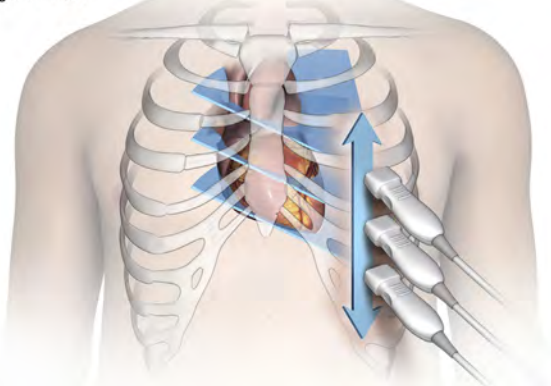


Figure 5 Sliding scanning maneuver.

bright white and low-amplitude signals as dark gray, with absence of signal being black. Signal manipulation is presented to the operator as a series of grayscale maps that allows the operator to select a setting that best displays images for a specific type of patient.¹⁷ Certain maps may show specific pathology better or may be better suited for patients on the basis of body habitus. Cardiac grayscale maps are designed to optimize the blood-tissue border (specular echoes) and demonstrate subtle differences in scattered echoes from weak reflectors, such as myocardium. Given the wide range of ultrasound systems available, the writing committee advises that all echocardiography laboratories work with application specialists from the manufacturer of the imaging systems to select optimal grayscale settings. Once laboratory protocols are selected, it is important to maintain consistent settings, as this may facilitate longitudinal comparisons with previous studies (Tables 1.1a and 1.1b).

2. B-Mode Colorization. Within the grayscale map selection, there is often an option for colorization of the B-mode image. In this

instance, the grayscale image is transformed to a different range of colors (e.g., sepia, a light pink color) instead of grays. Colorized B-mode may be a laboratory preference or an interpreting-physician preference. Some clinicians feel that the colorized image demonstrates certain pathologies better to their eye than the gray scale image.^{18,19} B-color does not change the amount or type of information displayed, only the perception of the viewer (Tables 1.2a and 1.2b).^{18,19,20}

3. Dynamic Range. An important grayscale parameter that adjusts the appearance of the shades of gray on the image is the dynamic range setting.^{10,17} On some ultrasound systems, this control is called “compression.”¹⁸ This setting changes the ratio between the highest and lowest received echo amplitudes in the image.^{10,17} A low dynamic range setting yields an image that is very black and white (high contrast). This may be beneficial for difficult studies with marginal image quality. A high dynamic range setting produces an image that has more shades of gray, which means that a smaller range of amplitudes is assigned to a particular shade of gray making up the image. For cardiac imaging, the dynamic range settings should be set to provide enough shades of gray to discern the interface between compacted and noncompacted myocardium. Too few shades of gray may result in an underrepresentation or absence of subtle, low-amplitude structures (e.g., a thin-walled segment, thrombus, or vegetation), while too many shades of gray may make the image appear “washed out,” sometimes eliminating accurate differentiation between the compacted and noncompacted myocardium (Tables 1.3a and 1.3b).

4. Transmit Frequency. *Transmit frequency* refers to the operating frequency of the imaging transducer. The typical range of frequencies used in adult echocardiography is 2.0 to 5.0 MHz. The higher frequencies produce better image resolution but are unable to penetrate as deep into the body as lower frequencies.^{10,17} With the availability of broad-bandwidth transducers, it is now relatively easy to modify transmit frequency rapidly. Operators should start with a high

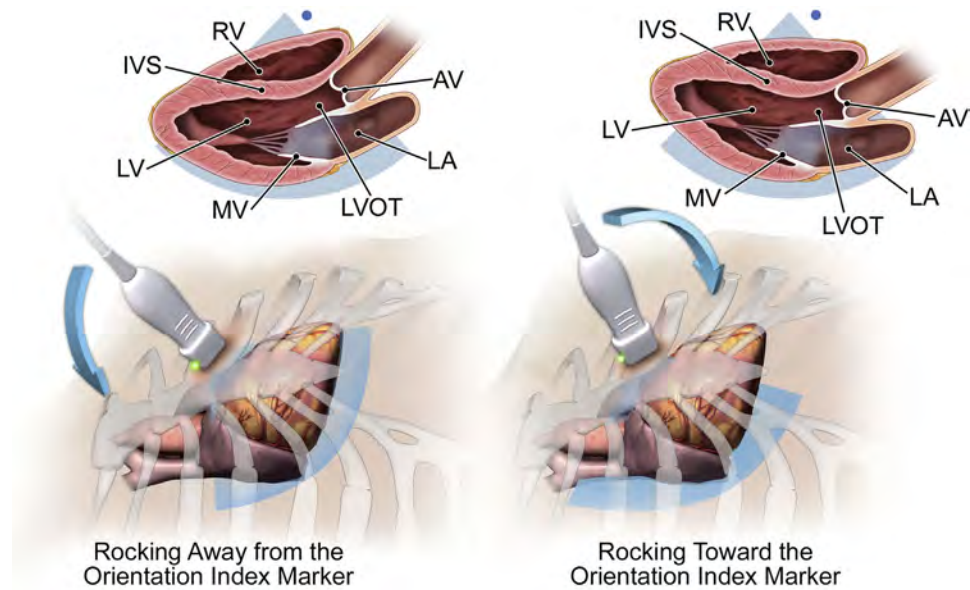


Figure 6 Rocking scanning maneuver. The *blue dot* represents the index orientation marker.

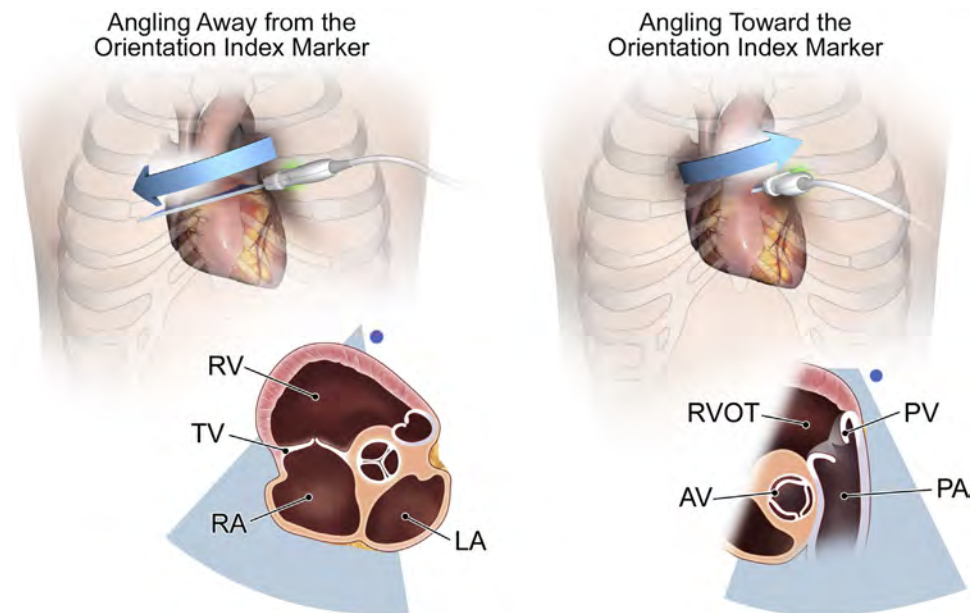


Figure 7 Angling scanning maneuver. The *blue dot* represents the index orientation marker.

transmit frequency and then adjust to lower frequencies if additional penetration of the sound wave is needed. The highest possible frequency should be used for imaging throughout the examination (Tables 1.4a and 1.4b).

5. Harmonic Imaging. Modern imaging systems allow the selection of harmonic imaging, where returning frequencies that are multiples of the transmit (fundamental) frequencies are used to create the ultrasound image. Harmonic frequencies are caused by the sound beam becoming distorted as it travels through tissues.^{10,17,21,22} Harmonic imaging most commonly uses the second harmonic frequency, which is twice the fundamental frequency.^{10,17,21,22} Manufacturers have lowered the fundamental

frequency of transducers to increase penetration while displaying the higher frequency second harmonic. This is especially helpful in patients who are obese or have dense muscle tissue and typically yields higher quality images. Because the degree of harmonic distortion is proportional to the strength of the reflected signal, higher energy specular echoes at tissue borders are enhanced while lower energy noise is eliminated. Thus, harmonic imaging results in an image that appears clearer with a maximized signal-to-noise ratio.^{10,17,21,22} With early forms of tissue harmonic imaging, axial resolution was negatively affected by the long pulse durations needed for frequency resolution. Newer forms of broad bandwidth tissue harmonic imaging have resolved this problem and allow low-artifact, high-axial resolution imaging.²³ The writing committee

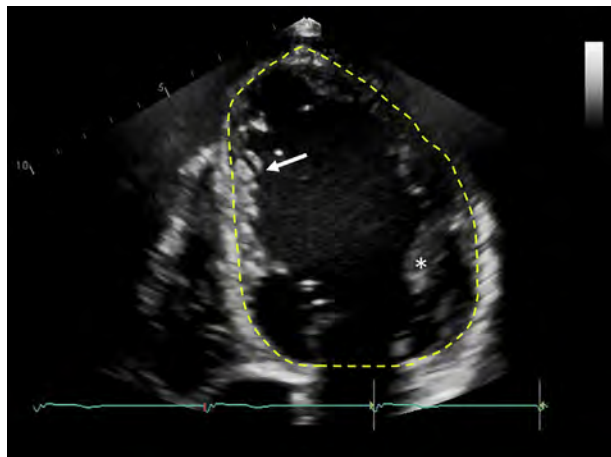


Figure 8 Tracing of the LV cavity in a patient with dilated cardiomyopathy. Note the prominent trabeculae (*arrow*) and papillary muscles (*asterisk*), which are considered part of the LV cavity.

recommends that cardiac ultrasound imaging be performed using harmonic imaging at the highest possible frequency (Tables 1.5a and 1.5b).^{22,24-28}

6. Sector Size and Depth. The depth setting of the image indicates how far into the body the ultrasound system attempts to detect anatomy. Depth is measured in units of length (such as centimeters or millimeters) and should be set to maximize the size of the display for the structures or flow of interest. Depth and sector width settings may also influence frame rates. Because the heart is a moving structure, higher frame rates are desirable to increase temporal resolution, particularly for rapidly moving structures. Unnecessarily large sector depths increase the amount of time needed to produce each imaging line of the sector, forcing the system to compromise, either by lowering frame rates or by reducing the number of lines per sector, resulting in reduced image quality. Similarly, a narrower sector angle may be appropriate in some circumstances to enhance image quality (Tables 1.6a and 1.6b).

7. Transducer Beam Focus. Some systems use automatic specialized dynamic focusing on the basis of the preset and the imaging depth. The operator cannot adjust this feature. Other systems have a manual transmit focus control that adjusts shape and width of the sound beam.¹⁷ Narrower widths yield better lateral resolution.¹⁷ The focus should be set at the depth of the structure of interest (Tables 1.7a and 1.7b). Note that in cases in which the apex needs to be evaluated, moving the focus to the apex may increase resolution. Typically, for cardiac imaging, a single focus is used to keep frame rates high and improve temporal resolution. Using multiple focal zones may decrease the frame rate, thus reducing temporal resolution.

8. Overall Gain and Time-Gain Compensation. Gain controls are designed to make tissues with similar acoustic properties appear consistent from one patient to the next and throughout the entire field of view.^{10,17} The overall gain adjusts the brightness of the image equally throughout the entire sector. Gain should be set high enough so that there are just a few echoes demonstrated in the blood and blood-endocardial tissue borders are well delineated (Tables 1.8a and 1.8b). The time-gain compensation (TGC) controls are usually set up as a series of

podds that can be adjusted to amplify a particular portion of the image. This control is used to make up for energy loss due to attenuation. Attenuation is the loss of ultrasound signal intensity and amplitude as it travels deeper into the body.^{10,17} Thus, returning signals from the near field of the sector have much greater amplitude than those from the far field. Selective amplification equalizes the appearance of structures across the entire sector (Tables 1.9a and 1.9b).

On some ultrasound systems, there is an automatic ultrasound optimization function that rapidly and automatically adjusts the TGC on the basis of the echo information returning to the ultrasound system.²⁹ Although this may be a time-saving feature for the operator, it should be used as a starting point for image optimization and not viewed as a definitive image adjustment (Tables 1.10a and 1.10b).

9. Zoom/Magnification. Another imaging feature is the zoom/magnification control. Most systems have two types of zoom/magnification available. There is a preprocessing zoom feature activated by placing a region of interest (ROI) within a small part of the sector and zooming. Although the number of pixels in the display is unchanged, each pixel now represents a smaller area in the heart. Because the ROI is small compared with the nonzoomed image, the frame rates can increase, and image resolution is improved. The second zoom feature is a postprocessing feature. In this case, after the image is frozen, an ROI is selected and the image is zoomed. This results in simple magnification of an anatomic structure. The number of pixels used to produce the image is the same as the original sector resolution. On the zoomed video display, fewer pixels are shown, but in an enlarged format, making the image larger but with poorer apparent resolution. The writing committee recommends using preprocessing zoom whenever possible (Tables 1.11a and 1.11b).

10. Frame Rate. There may be times when higher frame rates are desired to maximize temporal resolution. Operators can increase frame rates by decreasing the depth of the image, decreasing the number of focal zones, narrowing the sector width, or using preprocessing zoom.¹⁰ Depending on the imaging system, other image adjustments, such as reducing the number of scan lines being written per sector sweep, may increase frame rates (Tables 1.12a and 1.12b).¹⁰

B. Spectral Doppler

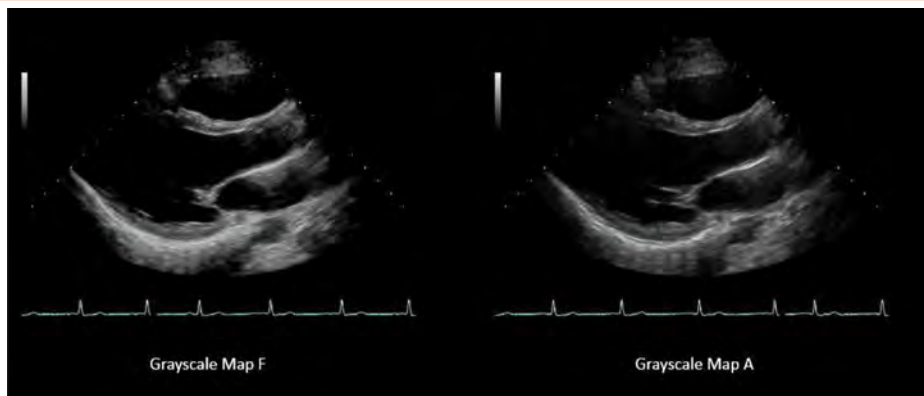
Spectral Doppler parameters that can be adjusted by the operator at the time of image acquisition include velocity scale, baseline position, sweep speed, velocity filters, sample volume size, and Doppler gain.^{10,30}

1. Velocity Scale. Adjusting the velocity scale allows the spectral Doppler tracing to be displayed as large as possible without aliasing (see below) (Tables 1.13a and 1.13b). By convention, flow toward the transducer is displayed above the zero-velocity baseline, and flow away from the transducer is displayed below the baseline on TTE imaging. However, most systems allow the operator to invert the signal. The baseline can be moved up or down to allow the Doppler signal to be displayed as large as possible without aliasing in either direction. However, the operator should take care not to miss important flow in the opposite direction.

2. Sweep Speed. The default sweep speed should be set to 100 mm/sec or adjusted to optimize the sweep display on the basis of heart rate.² Ideally, two or three spectral Doppler beats should be

Table 1 Instrumentation settings**Grayscale parameter and function****1.1. Grayscale map**

Determines how shades of gray will best be displayed to highlight specific findings in the image. (see [Videos 1 and 2](#))

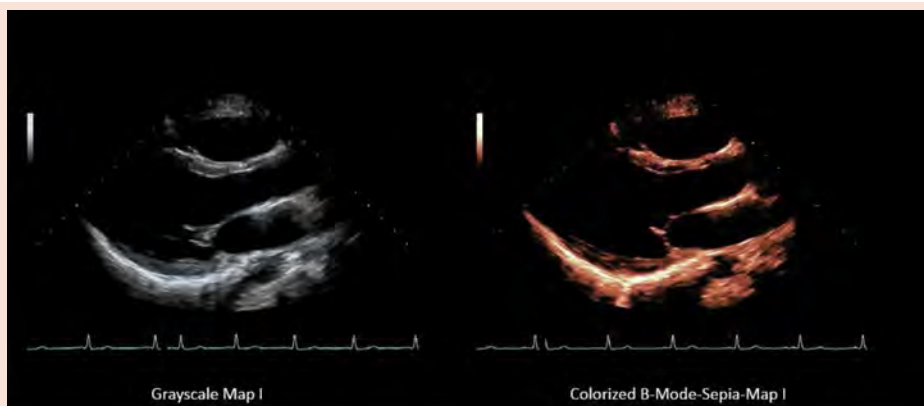


1.1a (see Video 1)

1.1b (see Video 2)

1.2. B-mode colorization

Transforms the B-mode image from standard shades of gray to an alternative color display. (see [Videos 3 and 4](#))

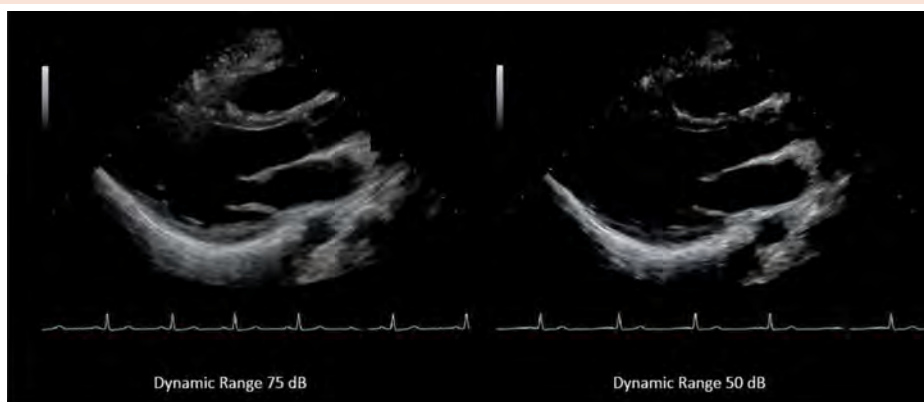

1.2a (see Video 3)

1.2b (see Video 4)

1.3. Dynamic range/compression

Shows the effect of two different settings of compression. (see [Videos 5 and 6](#))



1.3a (see Video 5)

1.3b (see Video 6)

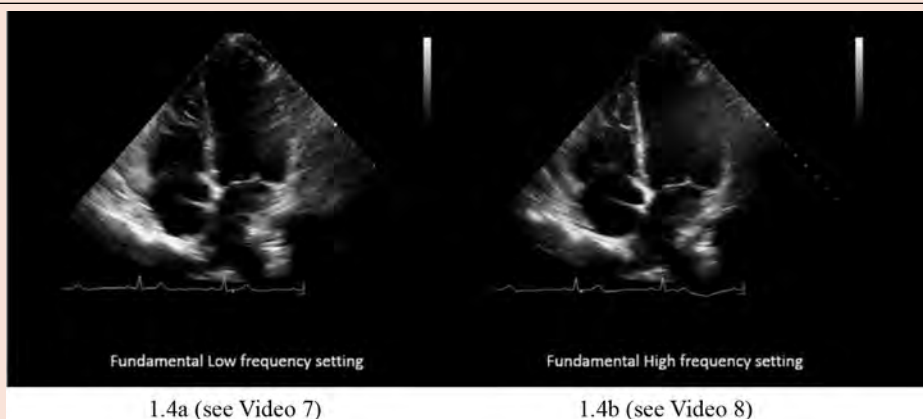
(Continued)

demonstrated across each sweep. This will allow visualization of more than one beat and allow accurate measurements of time intervals. In some instances, sweep speed should be adjusted to optimize the display for a specific diagnosis. For example, different sweep speeds may be used to assess mitral inflow. In one case, it may be desirable to increase the sweep speed to spread out the spectral waveform to

allow a more precise measurement of time, velocity-time integral (VTI), and slope. At other times when evaluating for physiology linked to the respiratory cycle, a slow sweep speed of 25 mm/sec is desirable to allow many beats to be seen simultaneously with a respirometer ([Tables 1.14a and 1.14b](#)).³¹⁻³³ All velocity and time interval measurements should be performed at a speed of ≥ 100 mm/sec.

Table 1 (Continued)

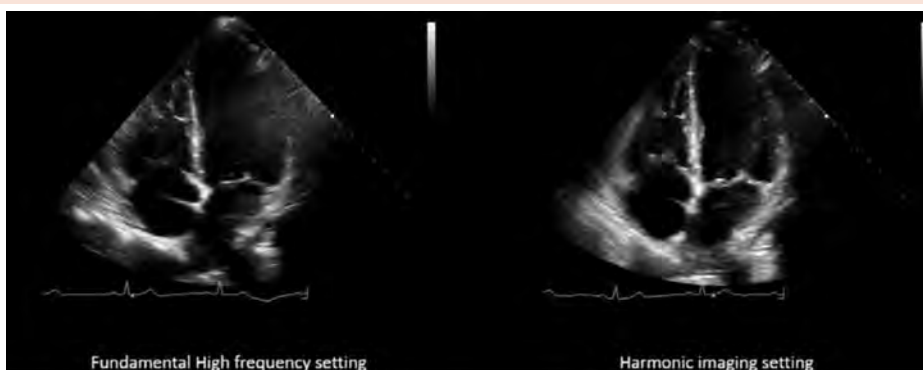
1.4. Transmit frequency
Shows the effect on image quality of two selections of frequency.
(see [Videos 7](#) and [8](#))



1.4a (see Video 7)

1.4b (see Video 8)

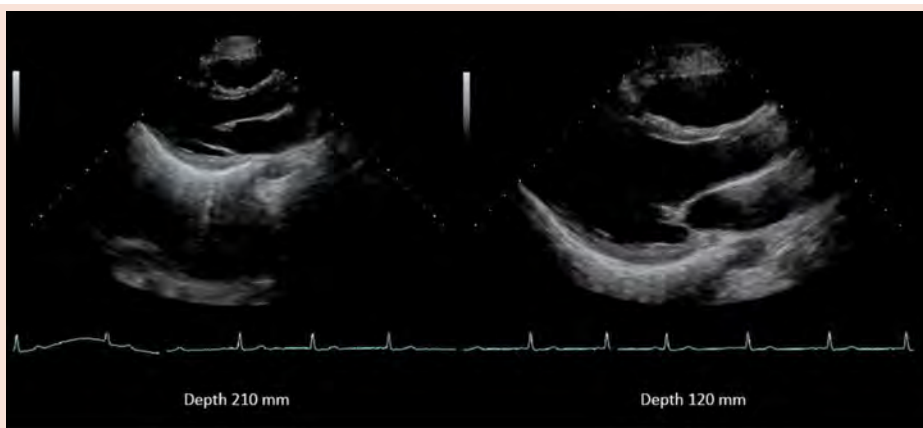
1.5. Harmonic imaging
Uses frequencies created by the tissues, rather than the fundamental frequency, to create an image. Most common is the second harmonic, which is twice the frequency of the fundamental.
(see [Videos 9](#) and [10](#))



1.5a (see Video 9)

1.5b (see Video 10)

1.6. Depth
Selects how shallow or deep the image will display. The image on the right demonstrates maximal use of the video display.
(see [Videos 11](#) and [12](#))



1.6a (see Video 11)

1.6b (see Video 12)

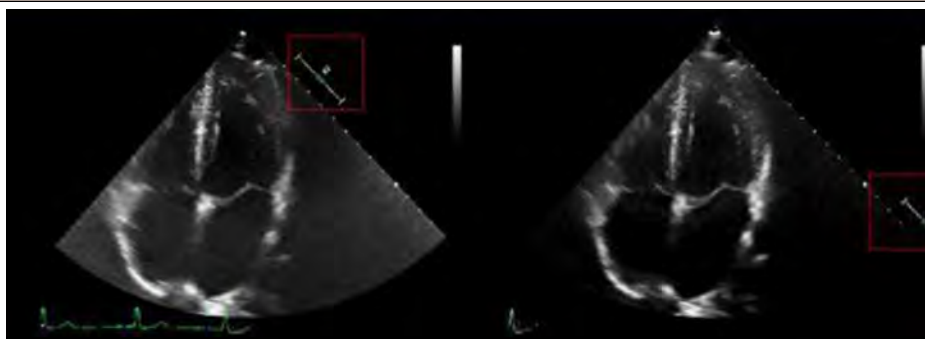
(Continued)

3. Sample Volume Size. The sample volume size feature should be used to decrease spectral broadening (noise within the spectral window) in order to display the clearest Doppler signal.^{10,34} If the sample volume is set too large, the Doppler signal may be inherently noisy, making it difficult to distinguish laminar from turbulent flow.³⁴ The appropriate sample volume size changes depending on which structure is being interrogated. Specific recommendations appear in later sections for individual imaging circumstances ([Tables 1.15a](#) and [1.15b](#)).

4. Wall Filters and Gain. Another adjustable spectral Doppler parameter is the wall filter. The wall filter allows the removal of high-intensity but low-velocity signals (“clutter”) from the Doppler spectrum that may emanate from movement of chamber walls or valve leaflets. It should be set to allow unambiguous display of the beginning and end of the flow signal of interest. In some instances, when signal velocity is very low, the wall filter may need to be set to a very low level to best detect the Doppler signal. In instances in which high velocities are present, the wall filter may

Table 1 (Continued)**1.7. Transducer beam focus**

Alters the beam shape and placement of the narrowed region of the sound beam, resulting in improved lateral resolution at the site of the focal zone. Note the clarity of the structure based on the focal zone placement (apex clarity, image 1.7a; MV and LA wall, image 1.7b). (see [Videos 13 and 14](#))

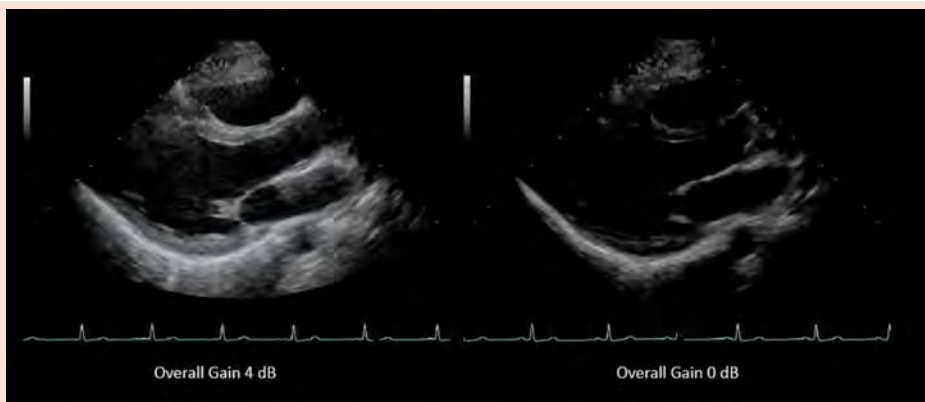


1.7a (see Video 13)

1.7b (see Video 14)

1.8. Overall gain

Controls amplification of returning echo signals before display. Adjusts the overall brightness or dimness of the image equally throughout the sector. Note the overall brightness of the image when the gain is set at 4 dB (image 1.8a) and overall gain set at 0 dB (image 1.8b). (see [Videos 15 and 16](#))

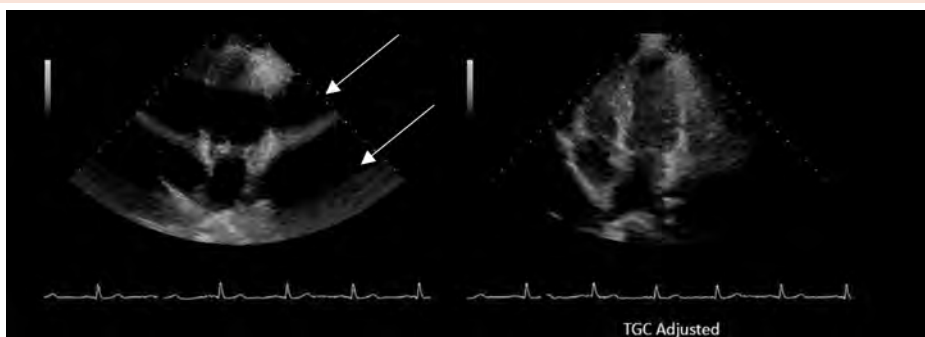


1.8a (see Video 15)

1.8b (see Video 16)

1.9. TGC

Selectively amplifies returning echo signals in different horizontal regions of the image before display. Note the appearance of focal banding when TGC pods at this area are not set correctly (arrows, 1.9a). Optimized TGC is image 1.9b. (see [Videos 17 and 18](#))

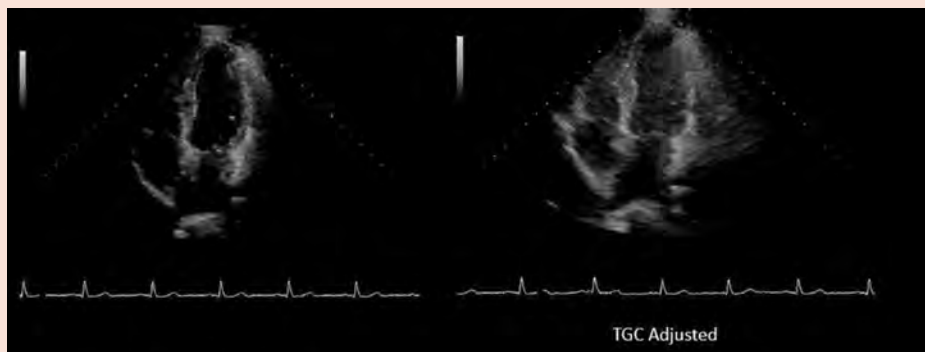

1.9a (see Video 17)

1.9b (see Video 18)

1.10. Automatic ultrasound optimization grayscale function

Auto-adjusts image TGC and gain settings on the basis of returning echo signals before image display. (see [Videos 19 and 20](#))



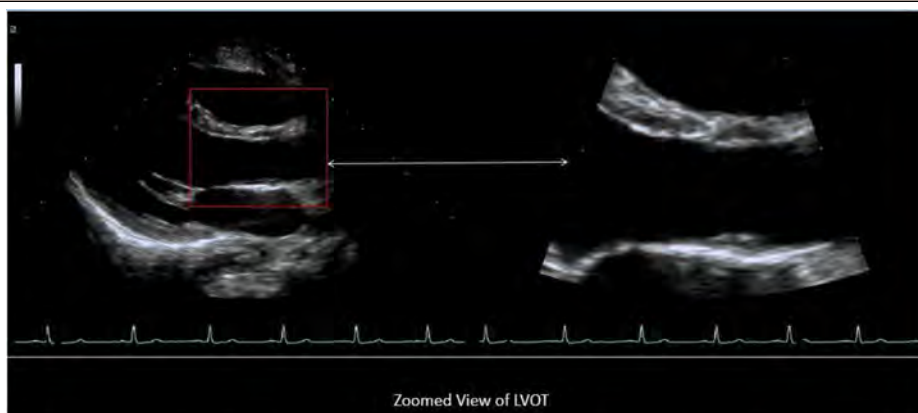1.10a (see Video 19)

1.10b (see Video 20)

(Continued)

Table 1 (Continued)**1.11. Zoom/magnification**

Magnifies a selected area of interest within the sector: Image 1.11a demonstrates the placement of the zoom box; Image 1.11b demonstrates the zoomed image. (see Videos 21 and 22)

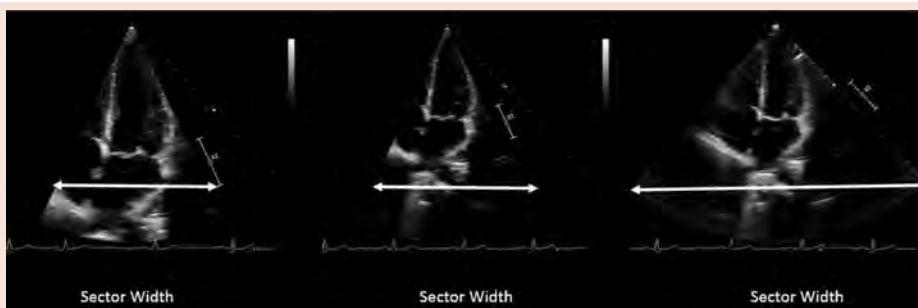


1.11a (see Video 21)

1.11b (see Video 22)

1.12. Sector size/frame

The changes in sector size and depth affect image display and frame rate. The left image (1.12a) is at a depth of 170 mm and uses a narrow sector width. The frame rate is 84 Hz. The middle image (1.12b) is at a depth of 240 mm with a narrow sector. The frame rate is 73 Hz. The right image (1.12c) is at a depth of 240 mm with a wide sector, and the frame rate is 43 Hz. (see Videos 23, 24 and 25)



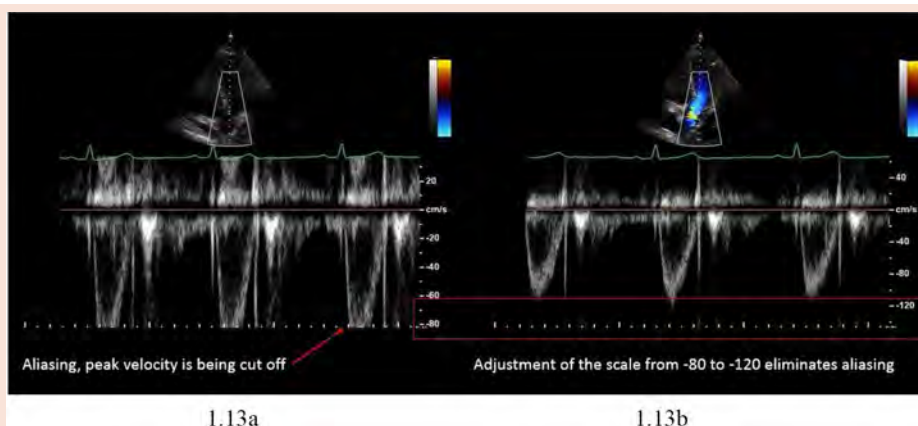
1.12a (see Video 23)

1.12b (see Video 24)

1.12c (see Video 25)

Spectral Doppler parameter and function**1.13. Velocity scale**

Specifies range of velocities that can be displayed. This is a PW Doppler sample from the LVOT. The image on the left demonstrates aliasing (1.13a). The velocity scale is adjusted from a maximum velocity range of -80.0 to -120 cm/sec. The right image (1.13b) has no aliasing.



1.13a

1.13b

(Continued)

need to be adjusted upward to remove more low-velocity clutter to allow an unambiguous display of the Doppler signal of interest (Tables 1.16a–1.16c).

As with grayscale imaging, the overall Doppler gain is adjusted to demonstrate the clearest Doppler signal that shows the full spectrum of velocities, displaying many shades of gray without missing important low-amplitude information (undergaining) or obscuring the true spectral envelope with excessive noise (overgaining) (Tables 1.17a–1.17c). The optimal signal for measurement is one that demonstrates a smooth velocity curve (Tables 1.17a–1.17c).³⁵ The modal velocity (densest portion of the Doppler signal) is the velocity measured.³⁵

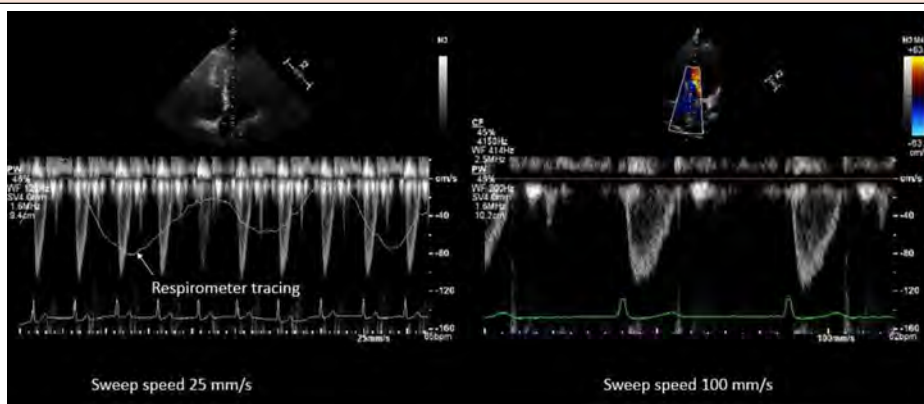
5. Display Settings. The spectral Doppler baseline should be positioned to optimally display the flow of interest. In some instances, such as when using continuous-wave (CW) Doppler to evaluate the PV, it may be desirable to demonstrate forward and regurgitant flow simultaneously on the same Doppler display.

Several systems also have an automatic ultrasound optimization feature that adjusts the spectral Doppler signal and includes positioning of the baseline, gain, and wall filter with one control. This can be a good starting point for image optimization (Tables 1.18a and 1.18b).

6. Pulsed-Wave Doppler, High-Pulse Repetition Frequency Doppler, and CW Doppler. Spectral Doppler consists of three

Table 1 (Continued)**1.14. Sweep speed**

Changes number of cardiac cycles shown on the horizontal axis of the Doppler display: 1.14a demonstrates a sweep speed of 25 mm/sec, and 1.14b demonstrates a sweep speed of 100 mm/sec.

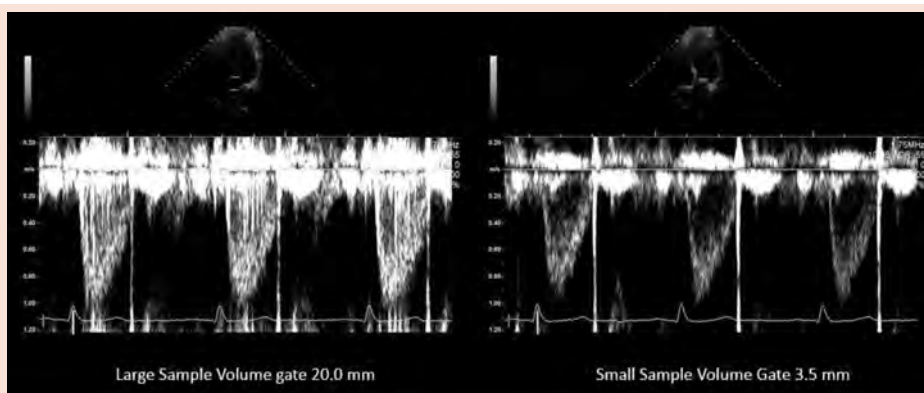


1.14a

1.14b

1.15. Sample volume size

The sample volume size adjusts the width of the sample volume. Image 1.15a demonstrates a large sample volume size. Note the noise in the Doppler signal. Image 1.15b demonstrates use of a smaller sample volume. Note the clarity of the Doppler signal.

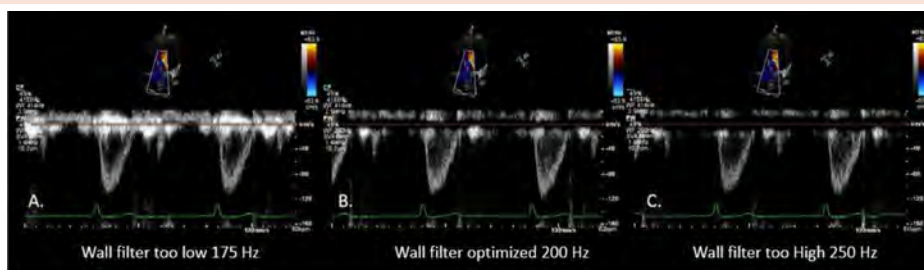


1.15a

1.15b

1.16. Wall filter

Eliminates low-velocity signals near the zero baseline



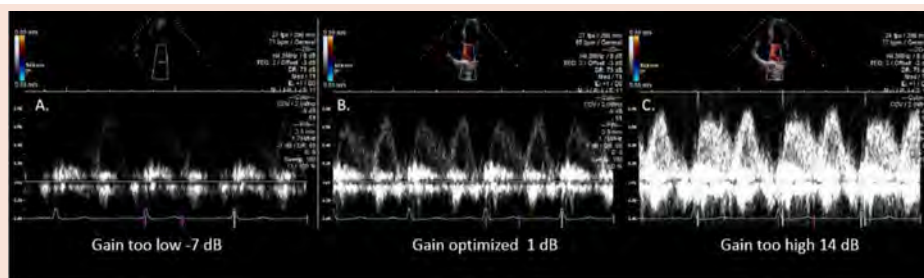
1.16a

1.16b

1.16c

1.17. Gain

Amplifies spectral Doppler signals before display. Proper adjustment of gain may have a profound effect on the ability to make accurate measurements.



1.17a

1.17b

1.17c

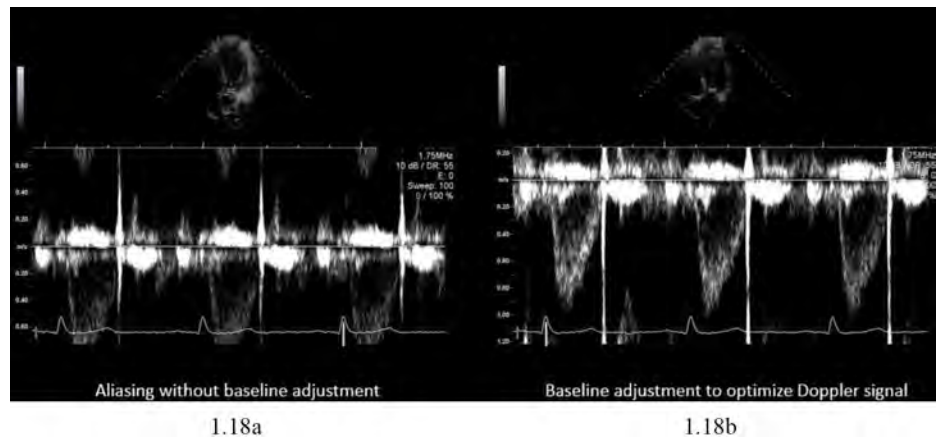
(Continued)

modes: pulsed-wave (PW) Doppler, high-pulse repetition frequency (HPRF) Doppler, and CW Doppler.^{17,30} PW Doppler is used when one wishes to measure blood flow velocity at a particular depth

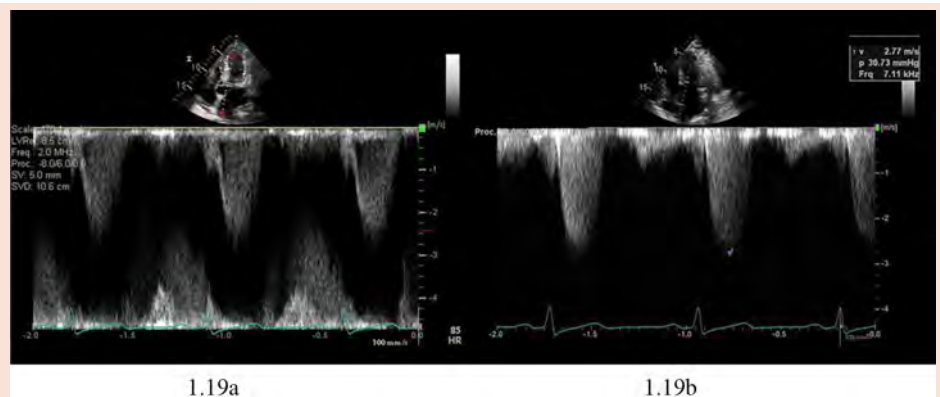
(range resolution). The major limitation of PW Doppler is aliasing, which is the inability to display a complete velocity waveform at excessively high velocities. Aliasing occurs when the detected

Table 1 (Continued)**1.18. Baseline**

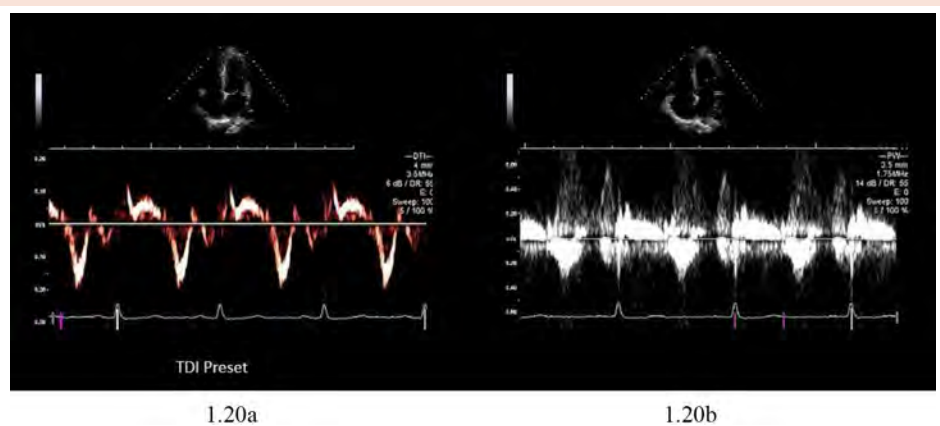
This control should be positioned to optimize the entire Doppler signal as large as possible and can be used along with the “Doppler scale” control to eliminate aliasing. Image 1.18a demonstrates improper baseline settings. Note the aliasing. Image 1.18b demonstrates optimization of the baseline.



1.19. Use of HPRF and CW Doppler to determine the highest velocity
Use of HPRF with multiple gates in image 1.19a. and CW Doppler in image 1.19b to acquire highest velocity.

**1.20. DTI**

DTI presets use larger sample volume size and lower velocity scales. Image 1.20a demonstrates an optimized DTI tracing. Image 1.20b demonstrates a DTI tracing with a smaller sample volume size and high-velocity scale setting. Note the difference in the quality of the DTI tracing.



(Continued)

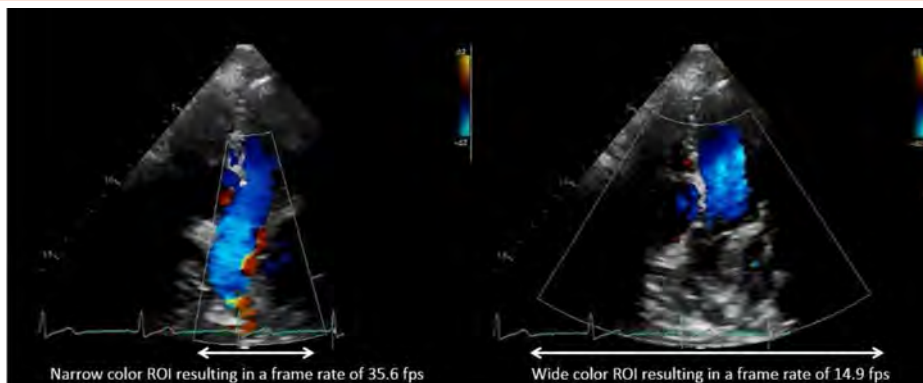
Doppler shift frequency is greater than half the pulse repetition frequency being transmitted into the heart.¹⁰ The pulse repetition frequency, which is the primary factor determining the maximum measurable velocity, or Nyquist limit, is determined primarily by velocity scale and is limited by maximum imaging depth. When aliasing cannot be eliminated in normal PW mode by maximizing the scale, switching to HPRF Doppler increases the number of active sample volumes. HPRF Doppler is used when the operator wishes to measure the blood flow velocity at a certain depth at which aliasing occurs with regular PW Doppler. For example, increasing the number of sample volumes to two increases the Nyquist limit by a factor of 2, and therefore higher velocities may be displayed.¹⁰ The major limita-

tion of this technique is range ambiguity, or an inability to determine the origin of the displayed velocities.¹⁰ With HPRF Doppler and two sample volumes, the displayed velocities could come from either sample volume. The clinical setting usually defines which sample volume is the source, but display artifacts may, in some situations, be difficult to define. Operators should know the characteristics of the imaging system being used, realizing that some systems automatically revert to HPRF when the velocity scale is increased, suddenly causing multiple sample volumes to appear (Tables 1.19a and 1.19b).

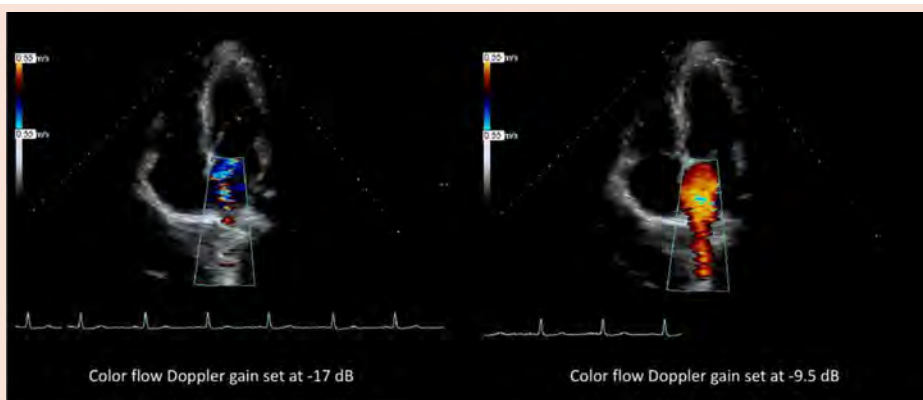
CW Doppler is used to measure and record high velocities. Although there is no Nyquist limit with CW Doppler, as transmission and reception of ultrasound are continuous, the limitation is range

Table 1 (Continued)**CDI parameter and function****1.21. Effect of sector size/ROI size**

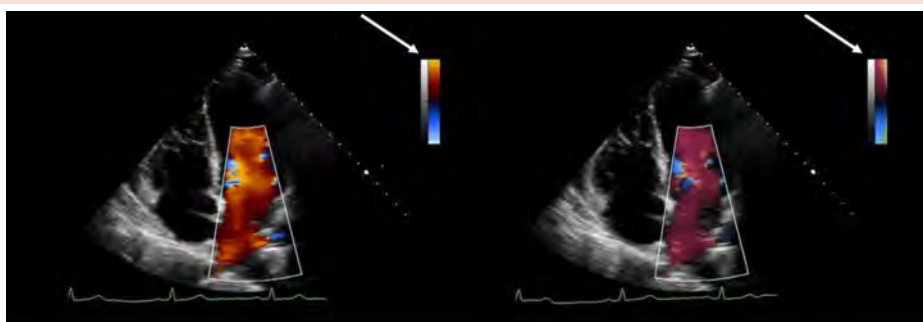
The size of the color flow Doppler ROI influences frame rate. Smaller color ROIs increase frame rate. To optimize the color image and keep frame rates high, the color ROI should be as narrow and small as possible while still including all relevant anatomy. (see [Videos 26](#) and [27](#))

1.21a (see [Video 26](#))1.21b (see [Video 27](#))**1.22. Gain**

Amplifies color Doppler signal before display. In this example, the image on the left has the color flow Doppler gain optimized to demonstrate flow in the Pulvns. In this example, the gain is increased from -17 dB (1.22a) to -9.5 dB (1.22b) to better demonstrate the Pulvns flow. (see [Videos 28](#) and [29](#))

1.22a (see [Video 28](#))1.22b (see [Video 29](#))**1.23. Color maps**

Converts velocities into colors. In 1.23a, high-velocity flow toward the transducer is displayed as yellow (arrow) and high-velocity flow away from the transducer as bright blue. In 1.23b, the Doppler map (arrow) displays velocity toward the transducer as shades of red color and flow away from the transducer as shades of blue with areas of turbulence as green. (see [Videos 30](#) and [31](#))

1.23a (see [Video 30](#))1.23b (see [Video 31](#))

(Continued)

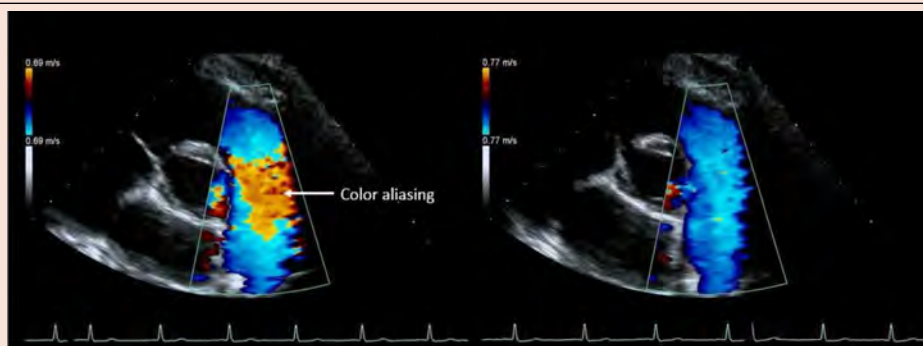
ambiguity.^{10,15} CW Doppler samples the entire range of returning frequencies along its beam path, and therefore it is not able to discern where any particular frequency shift is located.^{10,17,36} CW Doppler may be performed with duplex (combined imaging and Doppler) transducers that help define the source of the high-velocity flow. For maximum sensitivity, it is recommended that the small-footprint specialized nonimaging (pulsed echo Doppler flow) transducer be used for clinical situations in which it is critical to obtain maximum flow velocity.³⁷

7. Doppler Tissue Imaging. Doppler tissue imaging (DTI) is typically used to measure the Doppler frequency shift of the moving

myocardium and the annuli of the mitral and TVs.^{3,16,38,39} Both PW and color Doppler modes can be used with DTI.⁴⁰ Compared with measuring blood flow velocities, tissue Doppler detects very low velocities (<20 cm/sec) at a very high amplitude (>40 dB).^{3,16} Filter settings are much different compared with standard PW Doppler set for blood flow. To optimize this Doppler mode, it is recommended that a preset be used that is recommended by the ultrasound manufacturer.¹⁶ A preset for DTI will improve workflow for acquiring these Doppler data and serve as a quick starting point for optimizing the DTI signal. DTI presets have a larger sample volume than PW Doppler, the velocity scale set below 25 cm/sec, specialized filter and power settings, and sweep speeds selected as noted above

Table 1 (Continued)**1.24. Scale/PRF**

Specifies the range of velocities that can be represented by a color map without aliasing. In the image on the left (1.24a), color Doppler aliasing is noted in the PA. When the scale range is increased from 0.69 to 0.77 m/sec, the aliasing is eliminated (1.24b). (see [Videos 32](#) and [33](#))

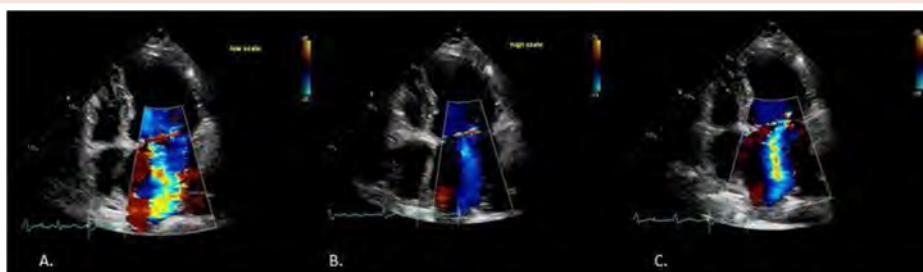


1.24a (see Video 32)

1.24b (see Video 33)

1.25. Effect of scale on display of regurgitation

Images 1.25a, 1.25b, and 1.25c are all taken from the same patient and demonstrate the effect of the color Doppler scale setting on the appearance of the mitral regurgitation jet. Image 1.25a: scale too low; image 1.25b: scale set too high; image 1.25c: scale setting optimized. (see [Videos 34](#), [35](#) and [36](#))



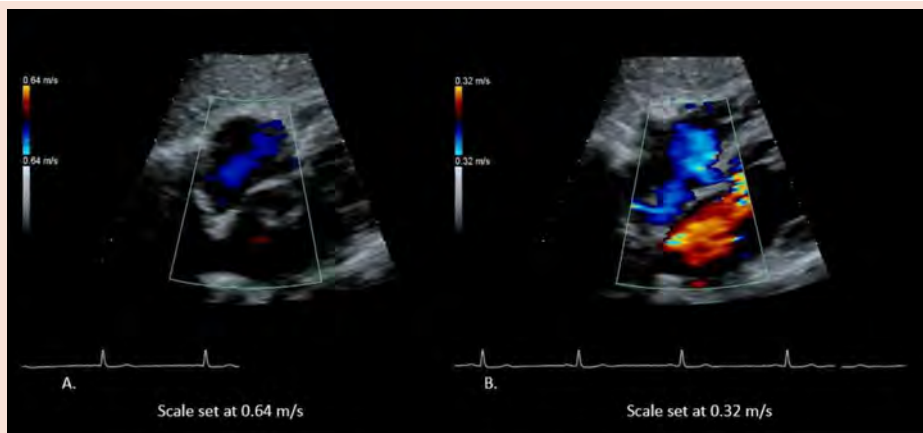
1.25a (see Video 34)

1.25b (see Video 35)

1.25c (see Video 36)

1.26. Low-flow settings of flow into the atrial septum

Image 1.26a demonstrates that scale set too high to evaluate the blood flow velocities in the atria. Image 1.26b demonstrates the scale set lower to optimize evaluation for low flow velocities in the atria. (see [Videos 37](#) and [38](#))

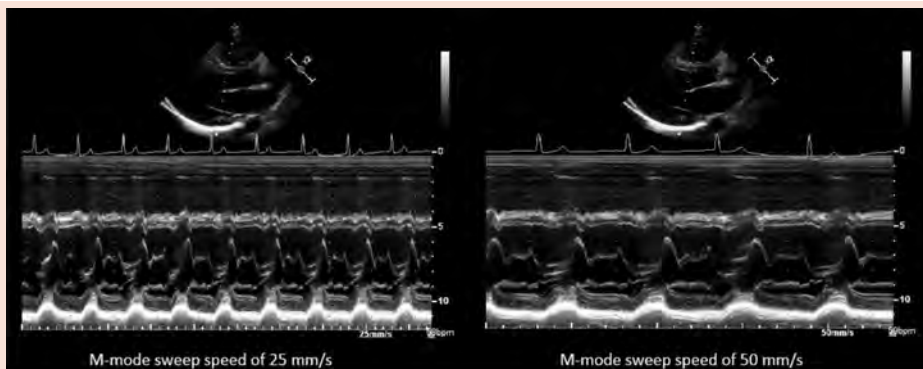


1.26a (see Video 37)

1.26b (see Video 38)

M-mode parameter and function**1.27. Sweep speed**

Changes number of cardiac cycles that can be shown on the horizontal axis of the M-mode display. Image 1.27a demonstrates a sweep speed of 25 mm/sec, and image 1.27b demonstrates a sweep speed of 50 mm/sec.



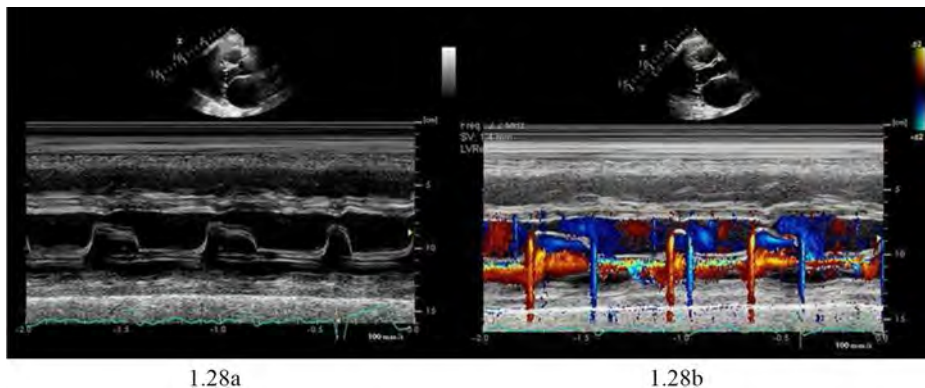
1.27a

1.27b

(Continued)

Table 1 (Continued)**1.28. Color M mode**

Color M mode assists with the timing of events. Image 1.28a demonstrates M mode with MS. In image 1.28b, color M mode demonstrates the inflow with MS in diastole and turbulent flow from MR in systole.



For Videos 1 to 38, see www.onlinejase.com.

for PW Doppler. Velocity and time interval measurements should be made at a sweep speed of 100 mm/sec (Tables 1.20a and 1.20b).⁴¹

C. Color Doppler Imaging

CDI is a pulsed Doppler technique that uses multiple sample volumes along a series of scan lines, displayed in an ROI.^{17,42} It is not a stand-alone display but rather is integrated with the 2D image and is affected by 2D gain settings. CDI displays the following blood flow characteristics: timing, relative velocity, direction, and presence of turbulence.³⁴ To best display color-flow data, several parameters should be optimized, including the size of the color ROI, 2D sector size, color-flow map, and velocity scale.

1. ROI and 2D Sector Size. Before initiating color Doppler, the 2D sector size should be adjusted to the lowest depth and width necessary to accurately depict the anatomic region to be imaged. This will help optimize the color frame rate.³⁴ In some settings, the preprocessing zoom mode may be the best alternative for the 2D display. The color box ROI defines the size and position of the region of color Doppler interrogation within the B-mode sector. The color box ROI should be sized to include all of the flow information being evaluated.³⁴ Setting the ROI as narrow and shallow as possible allows maximum frame rate and velocity scale, thus yielding the best temporal and flow velocity resolution (Tables 1.21a and 1.21b).³⁴

2. Color Gain. The color-flow Doppler gain should be adjusted by slowly increasing the color gain until there is random color-flow speckling beyond the borders of the anatomic area of interest, followed by slowly decreasing the gain until the speckling disappears. Color gain settings should be frequently adjusted during the examination, as variations in sound transmission and signal attenuation may result in unintended underrepresentation of flow if the gains are allowed to stay too low.

As with grayscale and spectral Doppler, the overall gain can also be adjusted to demonstrate the “best” flow through anatomic structures.³⁴ In some situations, if an anatomic structure is poorly visualized by grayscale imaging, increasing the color-flow Doppler gain may demonstrate filling of the structure (Tables 1.22a and 1.22b), confirming its presence.

3. Color Maps. The color map parameter defines how the imaging system displays flow and can be adjusted. The most basic maps display the direction of flow. Almost universally, there is a baseline with zero flow displayed as black. Typically, the CDI maps are set up so that flow toward the transducer is a red color map, while flow away from the transducer is a blue color map. The velocity range in each direction represents the

Nyquist limit for the imaging frequency and transducer being used. Typically, the scale setting is 50 to 70 cm/sec. To differentiate flow velocity, the map displays velocities in a set of hues or intensities, with dark shades depicting low velocity and bright shades representing the highest velocity (e.g., from deep red to bright yellow). Laminar flow tends to be depicted as a pure color, as velocities are relatively uniform. Turbulent flow, which contains a relatively random amalgamation of all velocities of the color map, is depicted as a multicolor mosaic. Color maps also may have features in which the operator can select a setting that will add shades of green and yellow colors to the map, which serve to highlight variance in flow velocity as an alternative method to differentiate turbulent from laminar flow. Each manufacturer has the basic red/blue map and its own set of proprietary maps. The echocardiography laboratory should choose a consistent map across all systems (Tables 1.23a and 1.23b).

4. Color Doppler Velocity Scale. Optimization of the color-flow Doppler velocity scale is an important feature that affects how color-flow jets are perceived. The scale setting is often displayed as a numeric value (usually in centimeters per second) seen on the color map. This numeric value represents the range of mean velocities that can be displayed. Setting the scale to high-velocity ranges demonstrates some color-flow data without aliasing (Tables 1.24a and 1.24b). This is particularly true for laminar flow through normal valves and blood vessels. As a default, it is recommended that the color-flow scale (Nyquist limit) be set between 50 and 70 cm/sec in each direction for all routine color Doppler interrogation.⁴³ This is particularly important for display of turbulent regurgitant valve jets. The size of the displayed regurgitant jet is affected by several variables, one being the Nyquist limit, in that the same regurgitant volume appears considerably larger at a lower color scale compared with a higher scale (Tables 1.25a–1.25c).⁴⁴ Consistent settings also enhance reproducibility of longitudinal studies for patients with chronic valve disease. Another important variable to record and report in all studies is blood pressure, because driving force across the regurgitant orifice also proportionally affects the displayed jet size.⁴⁵

High scale settings may have a significantly different effect when all of the flow in the interrogation box is at a low velocity. In this situation, the color box may demonstrate virtually no color Doppler signal, because most velocities fall within a narrow band of “dark” low velocity near the baseline on the color scale. Lowering the Nyquist limit makes the system display lower velocities in brighter hues by using the entire range of color display. A good starting point for low-flow states, such as in the atria (Tables 1.26a and 1.26b) or pulmonary veins (Pulvns), is a Nyquist limit of about 30 cm/sec.

As with grayscale imaging and spectral Doppler, several ultrasound systems also offer an automatic ultrasound optimization feature for color-flow Doppler settings. This feature permits automatic adjustment of the color scale and gain to help optimize color-flow Doppler images rapidly. The operator should understand the characteristics of this feature to best use it in multiple settings.

D. M Mode

Like the other modes, M mode has operator-controlled parameters to optimize images. Of most importance are overall gain, TGC, and sweep speed. These M-mode parameters work in a manner similar to spectral Doppler and B mode. A primary value of M mode is its superior time resolution, which enhances display of rapidly moving objects.^{10,46} Therefore, using rapid sweep speeds of 100 to 200 mm/sec is advantageous for making the most accurate time-related measurements. Other physiologic conditions that require observation of multiple beats may benefit from a slow sweep speed (Tables 1.27a and 1.27b). Specific M-mode motion patterns may define certain pathology better than any other modality. Similarly, the timing of movement of certain structures within the cardiac cycle is sometimes best delineated with M mode.¹⁰

1. Color M Mode. Color M mode integrates the color Doppler image with the M-mode tracing. It may be used to assist with timing of certain color-flow events within the cardiac cycle by markedly increasing the temporal resolution of a flow event. Examples in which this technology can be useful are timing of insufficiency jets in the cardiac cycle and the evaluation of LV inflow propagation velocity (Tables 1.28a and 1.28b).⁴⁷⁻⁴⁹

2. Steerable M Mode. Linear measurements are overestimated when obtained obliquely to the structure of interest. In some patients (e.g., those with “steep” hearts), it may not be possible to orient the M-mode cursor perpendicular to walls and chambers. Steerable M mode permits the M-mode cursor to be rotated, rather than maintaining a fixed origin at the narrow point of the 2D image sector. This allows the M-mode cursor to be directed perpendicular to a structure of interest, improving the accuracy of linear M-mode measurements in patients with steep hearts or off-axis views.^{50,51} Note that the image is created from selective display of a part of the 2D image. Therefore, temporal and range resolution are no better than the 2D image parameters, much inferior to directly obtained M-mode images.

E. Electrocardiographic Setup

It is important to have a good-quality electrocardiographic signal when performing echocardiography to determine timing of measurements. It is essential to have good “R” and “T” waves for digital image acquisition, as these signals trigger video clip acquisition.⁵² Poor-quality signals can result in incorrect triggering or inaccurate recording. In echocardiography, three electrocardiographic leads are used. The three leads are labeled right arm, left arm, and left leg. Typically, the right arm lead is placed near the right shoulder under the clavicle, the left arm lead is placed under the left clavicle, and the left leg lead is placed on the left side below the lower edge of the ribs.⁵³

Key Points #2

Instrumentation Settings

Two-Dimensional Imaging

Grayscale maps: Select grayscale maps that best fit the laboratory’s equipment, patient population,

and expected pathology. Be familiar with alternative grayscale maps for special circumstances.

Dynamic range: Select a consistent setting for the laboratory’s starting point. Adjust to a lower range for difficult studies and a higher range when more gray is necessary to display particular pathology.

Transducer frequency: Use broadband transducers with harmonics to optimize penetration and image quality. Start with high frequencies and adjust often throughout the examination to optimize image quality.

Sector size and depth: Use the entire sector to display the structure of interest at maximum frame rate and highest temporal resolution. This setting should be adjusted frequently throughout the examination and used in combination with zoomed settings to best display moving structures. Many measurements are best made in zoomed mode.

Gain: Frequently adjust and readjust the overall gain and TGC settings throughout the examination, always striving to optimize blood-tissue borders of the structure being interrogated.

Spectral Doppler

Velocity scale: Similar to sector size optimization, adjust the velocity scale display to unambiguously show flow signals. A larger signal on the display is more easily and accurately measured.

Sweep speed: Set the sweep speed to optimize measurements for the flow phenomenon being displayed. Faster speeds are best for timing flow-velocity integrals and slopes and slower sweep speeds for demonstrating respiratory-related flow changes.

Sample volume: Set the volume size to display the clearest spectrum signal depending on the structure being interrogated.

Gain: Set to show a smooth flow signal with an unambiguous modal velocity. Do not overgain. Avoid measuring weak, poorly defined signals outside of the major modal velocity.

Tissue Doppler: Use the manufacturer’s recommended presets to obtain an optimal velocity signal at the proper gain setting.

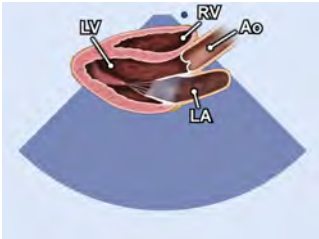
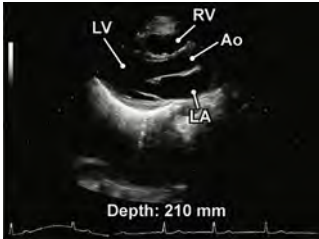
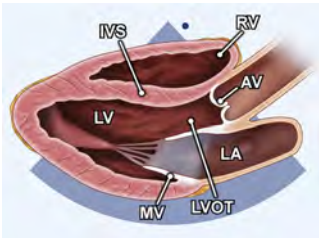
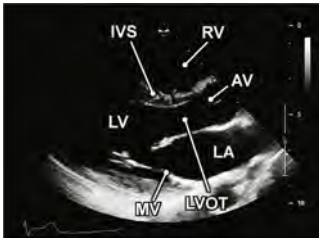

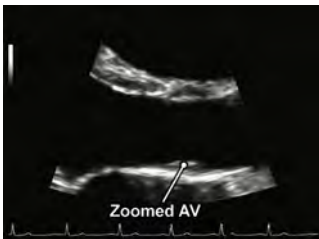


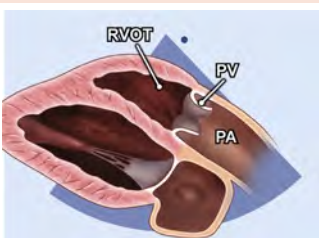
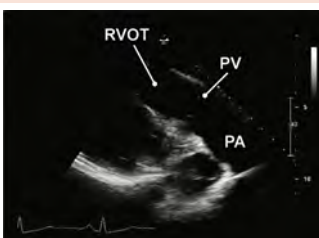
Color Doppler Imaging

Sector size: First optimize the 2D sector size, then add the color Doppler ROI sized appropriately to show the flow information being evaluated. A more narrow and shallow ROI optimizes frame rate and velocity scale.

Color gain: Set color gain just below the point of random speckle. Adjust the gains frequently throughout the examination to maximize display of flow.


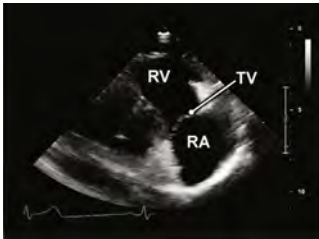
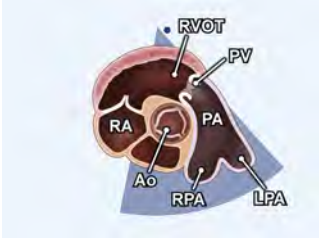
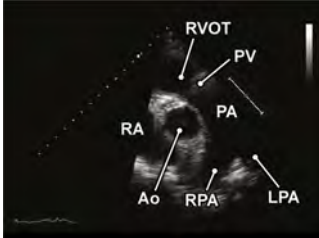
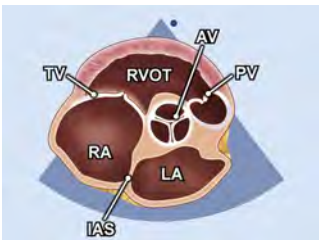
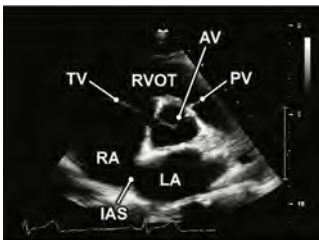
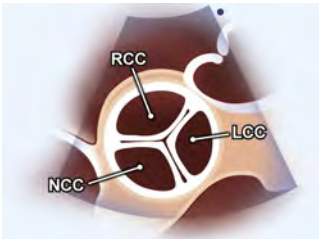
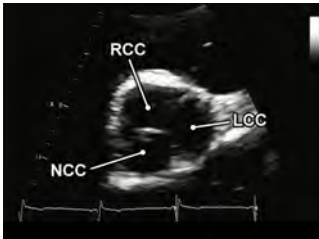

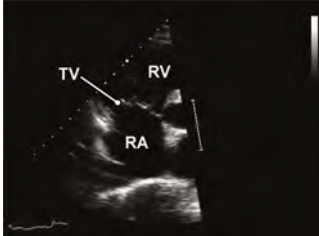
Color maps: Select a standard map for the laboratory at a consistent default scale setting (50–70 cm/sec). This will enhance consistency across studies and allow better longitudinal comparisons. In low-flow settings, adjust the velocity scale downward to better display the color Doppler image.

Table 2 Two-dimensional images and clips for imaging protocol

Anatomic image	2D TTE image	Acquisition image	Structures to demonstrate
2.1. PLAX increased depth (see Video 39)			
		Parasternal window PLAX view Left sternal border, transducer face orientation toward right shoulder	Pericardial space Pleural space
2.2 PLAX left ventricle (see Video 40)			
		Parasternal window PLAX view Left sternal border, transducer orientation toward right shoulder, beam positioned perpendicular to left ventricle	LA MV LV LVOT AV IVS RV
2.3. PLAX zoomed AV (see Video 41)			
		Parasternal window PLAX view ROI zoomed on LVOT, AV, and Asc Ao Image as perpendicular as possible to the structures and change to a higher interspace as needed	AV
2.4. PLAX zoomed MV (see Video 42)			
		Parasternal window PLAX view Adjust ROI to zoom on the MV Show full range of motion of both leaflets, proximal chordae, and annulus	MV LA
2.5 PLAX RV outflow (see Video 43)			
		Parasternal window PLAX view Tilted and rotated to the RVOT	RVOT PV PA

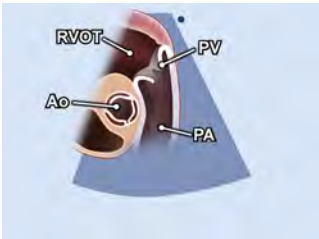
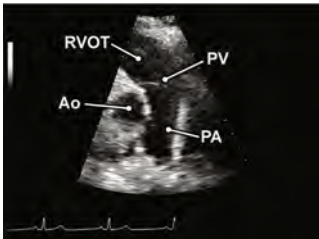
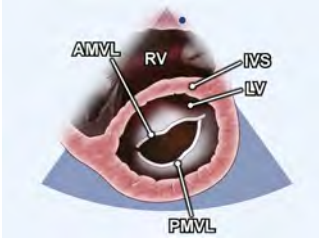
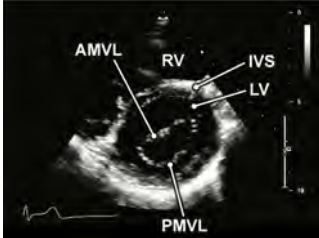
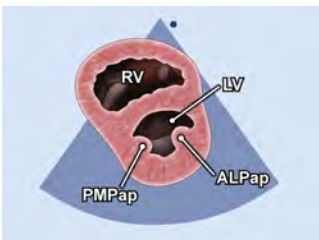
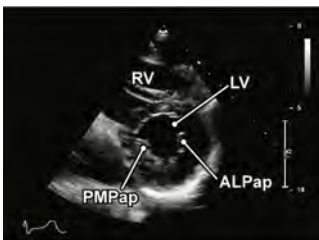

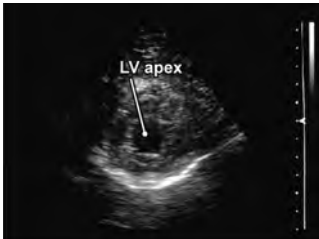
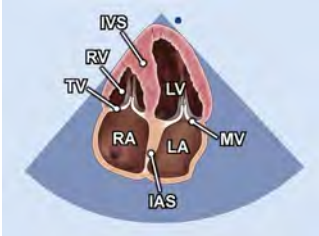
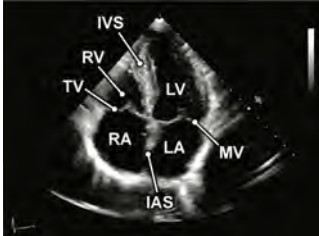
(Continued)

Table 2 (Continued)

Anatomic image	2D TTE image	Acquisition image	Structures to demonstrate
2.6. PLAX RV inflow (see Video 44)			
		Parasternal window PLAX view Tilt the face of the transducer inferiorly toward the right hip	RA TV RV
2.7. PSAX (level great vessels) focus on PV (see Video 45)			
		Parasternal window PSAX view Rotate 90° from the PLAX view and tilt superiorly	Ao RA RVOT PV PA PA branches
2.8. PSAX (level great vessels) focus on AV (see Video 46)			
		Parasternal window PSAX view Rotate 90° from PLAX window and tilt to identify structures at the level of AV	AV LA RA TV RVOT PV IAS
2.9. PSAX (level great vessels) zoomed AV (see Video 47)			
		Parasternal window PSAX view Zoomed on AV to demonstrate all leaflets	NCC RCC LCC
2.10a. PSAX (level great vessels) focus on TV (see Video 48)			
		Parasternal window PSAX view Zoomed to focus on TV	RA TV RV



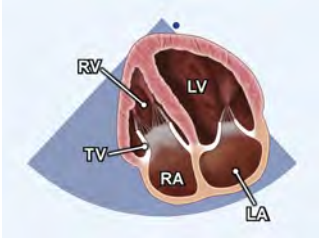

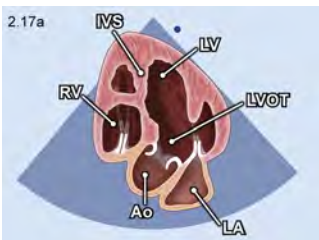

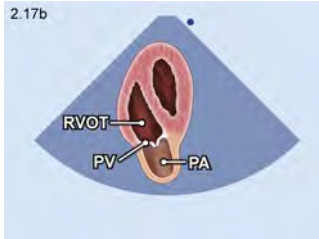
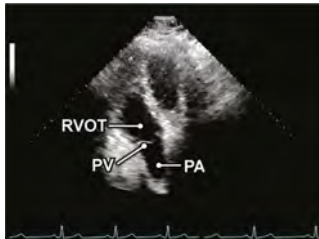
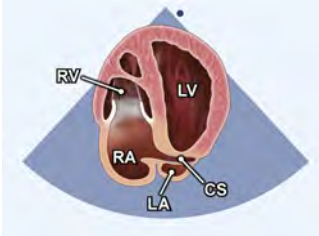
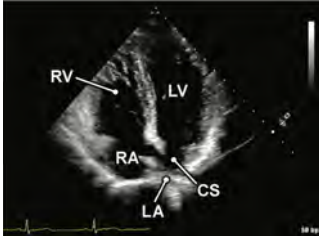
(Continued)

Table 2 (Continued)

Anatomic image	2D TTE image	Acquisition image	Structures to demonstrate
2.10b. PSAX focus on PV and PA (see Video 49)			
		Parasternal window PSAX view Focus on PV and PA	RVOT PV PA Ao
2.11. PSAX (level of MV) (see Video 50)			
		Parasternal window PSAX view Tilt inferiorly from the great vessel level	RV IVS AMVL PMVL LV
2.12. PSAX (level of papillary muscles) (see Video 51)			
		Parasternal window PSAX view Tilt inferiorly from the MV	RV IVS PMPap ALPap LV
2.13. PSAX (level of apex) (see Video 52)			
		Parasternal window PSAX view Tilt inferiorly from the papillary muscles	LV apex
2.14. A4C (see Video 53)			
		Apical window 4C view Move to patient's left side, identify apical impulse, align orientation toward bed	LA MV LV IVS RV TV RA IAS

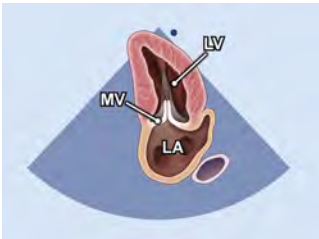

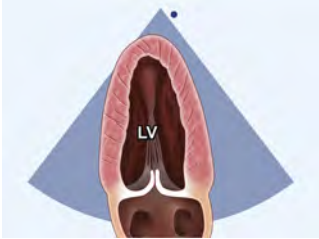

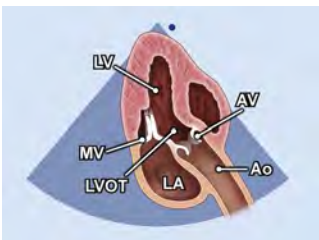
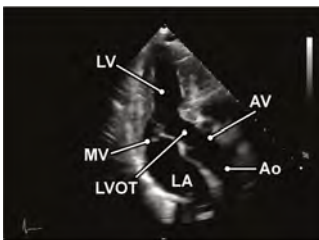


(Continued)

Table 2 (Continued)

Anatomic image	2D TTE image	Acquisition image	Structures to demonstrate
2.15. A4C zoomed left ventricle (see Video 54)			
		Apical window 4C view Optimize depth setting to focus on LV A4C view	LV
2.16. A4C RV-focused (see Video 55)			
		Apical window RV-focused A4C view Rotate the transducer to maximize the RV area and lateral dimensions	RA TV RV LA LV
2.17. A5C (see Videos 56 and 57)			
		Apical window 5C view From the A5C view tilt the beam anteriorly to show the LVOT	LA MV LV IVS LVOT RA RV
		Apical window 5C view From the A5C view tilt anteriorly to demonstrate the RVOT, PV, and PA	RVOT PV PA
2.18. A4C posterior angulation (see Video 58)			
		Apical window 4C view From the A4C view tilt the beam posteriorly to show the CS	CS RA RV LV LA

(Continued)

Table 2 (Continued)

Anatomic image	2D TTE image	Acquisition image	Structures to demonstrate
2.19. A2C (see Video 59)			
		Apical window 2C view From the A4C view rotate 60° counterclockwise to show the A2C view	LV MV LA
2.20. A2C zoomed left ventricle (see Video 60)			
		Apical window 2C view Optimize depth setting to focus on LV A2C view	LV
2.21. Apical long axis (see Video 61)			
		Apical window 3C view Rotate 60° counterclockwise from the A2C view to show the 3C view	LA MV LV LVOT AV
2.22. Apical long axis zoomed left ventricle (see Video 62)			
		Apical window 3C view Optimize depth setting to focus on LV 3C view	LV

(Continued)

IV. TWO-DIMENSIONAL IMAGING PROTOCOL

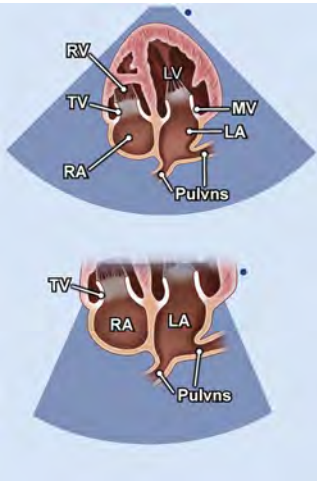
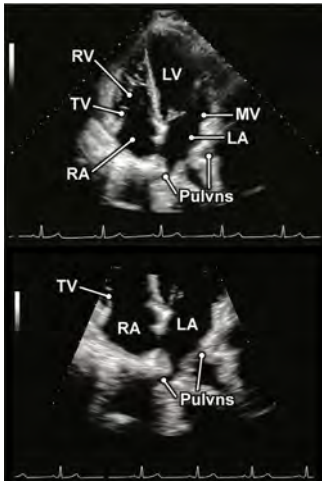
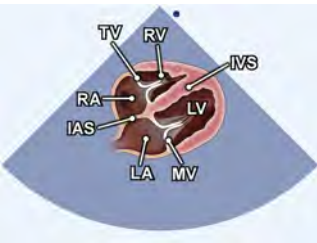
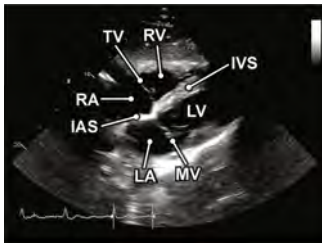
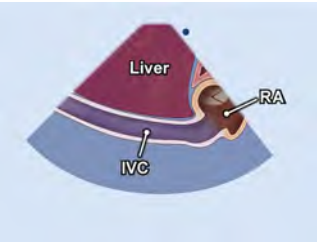
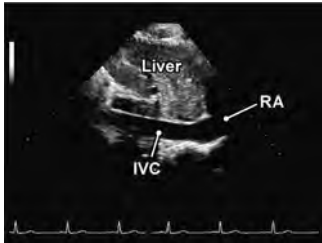
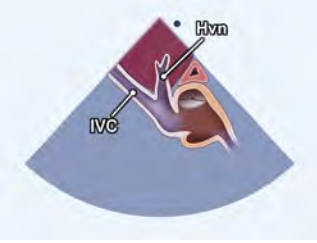
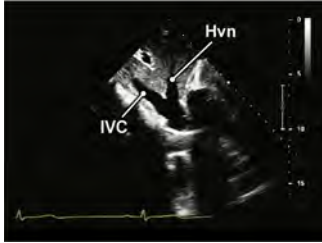
This section contains a sequential series of 2D images that constitute the essential views of a complete examination. Subsequent sections will present essential elements of the Doppler examination and measurements involving these echocardiographic modalities. Following these sections, the full sequence of an integrated examination is presented. Laboratories should establish standards for image acquisition. Clinical circumstances may dictate variations in the number of loops needed, but it is essential that an adequate number of loops are acquired for each view to accurately represent cardiac anatomy and performance. Furthermore, standardized methods for recording clips for measurement are recommended. Derived function assessments that

require multiple measurements should always be taken from the same heartbeat (e.g., diastolic and systolic volumes for calculating ejection fraction). Measurements should be taken from the recorded video clips and saved as separate still frames. This will permit a full understanding of how each measurement was obtained and allow re-measurement after the examination is completed, if necessary.

A. PLAX View

The examination is begun by positioning the patient in the left lateral decubitus position.^{5,14} The transducer is placed in the third or fourth intercostal space to the left of the sternum, with the index marker pointed to the patient's right shoulder at approximately the 9 to 10 o'clock position.^{14,54} If possible, the left ventricle should appear

Table 2 (Continued)

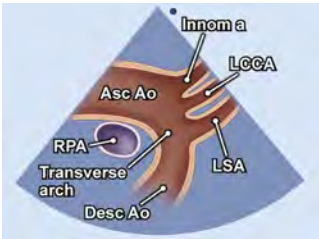
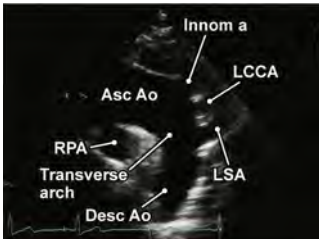
Anatomic image	2D TTE image	Acquisition image	Structures to demonstrate
2.23. A4C LA Pulvns focus (see Videos 63 and 64)			
		Apical window 4C view Optimize image to focus on left atrium and Pulvns	Pulvns LA MV LV RA TV RV
2.24. SC 4C (see Video 65)			
		SC window 4C view Patient supine Transducer at subxiphoid position, orientation index marker pointing toward the patient's left shoulder Held inspiration	LV MV RV TV IAS IVS RA LA
2.25. SC long axis IVC (see Video 66)			
		SC window IVC view Long axis on patient's body	Long axis IVC
2.26. SC window Hvn (see Video 67)			
		SC window From the IVC view, angle slightly rightward and rock superiorly	IVC and Hvn

(Continued)

positioned perpendicular to the ultrasound beam within the image sector. If the ventricle does not appear relatively horizontal, the transducer may be moved to a higher parasternal window or the patient turned to a steeper left lateral decubitus position. In a

majority of patients, the apex should not be seen in the PLAX view. The appearance of a "false apex" and a short left ventricle may be eliminated by rotating, tilting, and/or angling the transducer, thus maximizing the LV cavity length within the field of view.¹⁴

Table 2 (Continued)

Anatomic image	2D TTE image	Acquisition image	Structures to demonstrate
2.27. SSN aortic arch (see Video 68)			
		SSN window Aortic arch view Index facing 12 o'clock, rotate the transducer toward the left shoulder (1 o'clock), and angle toward the plane that cuts through the right nipple and the tip of the left scapula	Asc Ao Transverse arch Desc Ao Innom a LCCA LSA

For Videos 39 to 68, see www.onlinejase.com.

1. PLAX View: Left Ventricle. After finding the best PLAX image, imaging depth should be increased to interrogate beyond the posterior wall, evaluating for any abnormal conditions such as pleural or pericardial effusions (Table 2.1). This “scout view” is the first captured clip. The next clip is obtained after reducing the depth to optimally fit the full PLAX view in the sector, leaving about 1 cm of depth beyond the pericardium. This clip should be positioned to show movement of two of three AV leaflets and both mitral valve (MV) leaflets (Table 2.2). Next, the zoom function should be used to optimally visualize the AV and LV outflow tract (LVOT).¹⁴ Often, the optimal long axis of the LVOT and aorta is different from that of the left ventricle, and repositioning is required to demonstrate the best view of the LVOT and aorta. Particular attention should be paid to valve motion and image quality for linear measurements of the LVOT and aorta. The transducer should be slid slightly toward the sinotubular junction and a video clip obtained (Table 2.3). After freezing the image, the trackball is scrolled to the frame demonstrating the closed AV, and attention is paid to the closed valve, sinotubular junction, sinus of Valsalva (SoVAo), and ascending aorta (Asc Ao) to make sure image quality is suitable for measurement.² If necessary, the transducer may be positioned one or two interspaces higher or the patient repositioned to obtain a more complete view of the Asc Ao. It may be helpful to obtain this image with the patient holding end-expiration. The first several centimeters of the aorta should be visible. Next, the zoom box ROI is positioned over the MV to demonstrate motion of the anterior and posterior leaflets. The ROI should also adequately demonstrate the left atrium and the inflow portion of the left ventricle. This is the final video clip of the PLAX view (Table 2.4).

2. Right Ventricular Outflow Tract View. The right ventricular outflow tract (RVOT) view visualizes the PV and outflow of the right ventricle. To obtain this view, the transducer is tilted anteriorly from the PLAX view and rotated slightly clockwise.^{54,55} The cardiac structures visualized in this view include the RVOT, two leaflets of the PV, the main pulmonary artery (PA), and in some instances the bifurcation of the PA. A clip of this view should be recorded (Table 2.5).

3. Right Ventricular Inflow View. The right ventricular (RV) inflow view is obtained by tilting the transducer inferiorly toward

the patient's right hip.^{54,55} Additional counterclockwise rotation of the transducer may be necessary to optimally demonstrate the anterior and a second leaflet of the TV. Depending on orientation, the septal leaflet (if the septum is in view) or the posterior leaflet (if the septum is not visible) is present. The TV should be in the center of the sector, with considerable portions of the right ventricle visualized in the upper part of the sector. To the upper right is the anterior wall of the right ventricle and to the left is the inferior wall of the right ventricle. The right atrium and in some circumstances the Eustachian valve, Eustachian ridge, coronary sinus (CS), and the proximal inferior vena cava (IVC) are in the lower part of the sector. A clip of this view should be recorded (Table 2.6).

B. PSAX Views

The PSAX views are obtained by rotating the transducer 90° clockwise from the PLAX view to position the beam perpendicular to the long axis of the left ventricle.^{5,14,54} Several anatomic structures are imaged by tilting the transducer first superiorly and then progressively inferiorly to multiple levels. The first image begins at the level of the great vessels (aorta and PA). In this view, the aorta above the valve is seen in cross section, and the RVOT, PV, main PA, and beginning of the left and right branches of the PA are visualized. Image quality and structure visualization may be improved by moving the transducer up one interspace. A clip should be recorded at this level (Table 2.7).

Tilting inferiorly reveals the PV, AV (all three leaflets), and TV aligned from right to left across the sector.⁵⁴ An initial larger sector view should be taken to view the left atrium directly below the AV, the interatrial septum, and the transition to the right atrium. Portions of the left atrial (LA) appendage may be visible on the right side of the sector in some patients.¹⁴ In the upper sector, care should be taken to demonstrate the transition of the right ventricle from the inflow to the outflow positions (Table 2.8). Each valve should be interrogated using manipulation of the sector size or use of the zoom function. A clip should be taken of the zoomed AV to demonstrate leaflet number and motion (Table 2.9). At this level, further fine manipulation can demonstrate the origin of the left main coronary artery at about 3 to 5 o'clock in the area of the left coronary cusp.⁵⁶ Additional transducer movement toward the right coronary cusp may show the origin of the right coronary artery at about 11 o'clock.⁵⁶ Views of the origin of the coronary arteries are not

considered part of the routine examination. Given variable clinical needs of the population served, each echocardiography laboratory should develop a policy on routine inclusion of imaging of the coronary artery origins. Next, the sector should be adjusted to demonstrate the anatomy and motion of the TV leaflets. Also, the full right atrium, the inflow section into the right ventricle, and areas around the high ventricular septum should be demonstrated. Multiple clips may be needed at this level (Table 2.10a). After interrogating the TV, the transducer is angled toward the RVOT and PV and a clip acquired (Table 2.10b).

From the level of the great vessels, the transducer is tilted inferiorly and slightly leftward toward the apex of the heart, stopping at the level of the MV.^{14,54,55} In this view, maximum excursion of both the anterior and posterior leaflets of the MV should be clearly demonstrated. The right ventricle appears as a crescent at the top and left portions of the sector. The anterior, lateral, and inferior walls of the left ventricle are visible. Settings should be adjusted to obtain a clear view of the free wall. A clip should be taken showing the MV and RV (Table 2.11).

Next, the transducer is tilted to a location just inferior to the tips of the mitral leaflets, at the level of the papillary muscles.^{14,54,55} The ventricle should appear circular, and the papillary muscles should not wobble. This is approximately at the mid-LV level and is a particularly important view to judge LV global and regional function. Imaging settings should be carefully adjusted to optimally demonstrate myocardial motion and thickening. The right ventricle continues to be present at the anterior and medial portion of the sector. At least two clips at this level should be acquired (Table 2.12).

The last PSAX video clip to be acquired is at the level of the apical third of the ventricle.^{14,54,55} This may require tilting or sliding the transducer down one or two rib interspaces and laterally to best see the apex. The right ventricle is usually no longer present in the sector (Table 2.13).

C. Apical Views

After the PSAX views are completed, the apical window is next to be interrogated.^{5,14} The apical position is usually found on the left side of the chest near the point of maximal impulse, aligned near the midaxillary line, as most people present with levocardia. A good starting point is the fifth intercostal space, but it should be noted that there is often more than one apical window that can be used during the examination. The term *axis* has been used for the ideal projection of ultrasound through the apex of the ventricles, atrioventricular valves, and atria in a vector that maximizes the long axis of the heart.¹⁴ Ideally, this view would be available in every patient, allowing optimal image quality. However, this is not always the case, as ultrasound transmission is limited to the rib interspaces. Changes in cardiac structure due to cardiac pathology and changes in the structure of the thoracic cavity may also render the ideal view impossible. To best position the transducer for the apical views, a specialized cut-out bed that better exposes the apex is strongly recommended. Throughout the examination, repositioning of the patient may improve image quality of various apical views. In general, when imaging in the apical window in a normal heart, the long axis from the base of the left atrium to the apex of the left ventricle should consist of about two thirds left ventricle and one third left atrium. This is a helpful subjective guide to know that the left ventricle is not being foreshortened. In addition, the left ventricle should taper to an ellipsoid shape at the apex. If the ventricle is foreshortened, the apex will appear more rounded.⁹

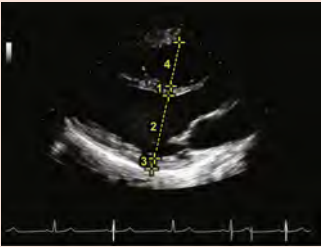
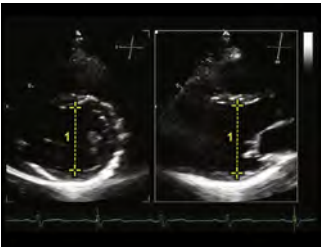
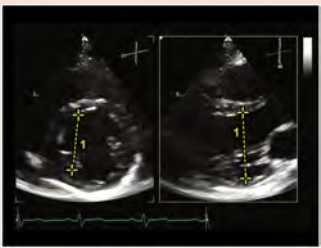

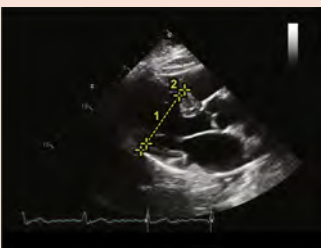

1. A4C View. The first apical view to be acquired is the A4C view. To obtain this view, the transducer is placed at the palpated apical impulse with the index marker oriented toward the bed. The image is optimized so that all four chambers are seen, with left-sided structures appearing on the right side of the displayed sector and right-sided structures on the left.¹⁴ In the normal heart, the apex of the left ventricle is at the top and center of the sector, while the right ventricle is triangular in shape and considerably smaller in area. The myocardium should be visible uniformly from the apex to the atrioventricular valves and the moderator band identified in the apical part of the right ventricle. Full excursion of the two mitral leaflets and two of the tricuspid leaflets (septal and posterior or anterior) should be identified. The walls and septa of each chamber should be visualized to assess for size and performance measurements.² Observing this view during respiration allows the operator to assess for ventricular interdependence, septal motion abnormalities, and aneurysmal atrial septal motion. The initial video clip should encompass a full view of all four chambers, including full visualization of the atria to put overall chamber size into perspective (Table 2.14). To facilitate quantification and observation of regional wall motion, the sector size should be reduced to include only the ventricles. This smaller sector size is also recommended for longitudinal strain imaging and 3D volume acquisition.⁵⁷ An additional one or two 2D clips, as well as additional clips for advanced imaging, should be recorded at this level of magnification (Table 2.15).

2. Right Ventricle–Focused View. To obtain the right ventricle–focused view, the A4C view should initially be obtained. The transducer is then rotated slightly counterclockwise while keeping it at the apex to maximize the RV area in this view. The plane should be maintained in the center of the left ventricle, avoiding tilting anteriorly into a five-chamber view. Fine adjustments should be made to maximize the visualized area of the right ventricle.^{58,59} This view is recommended for RV linear and area quantification. Alternative transducer positioning by tilting toward the right heart or sliding to a more medial window in a superior rib space may be necessary in some patients. Either maneuver can be used to align the vector of the TV annulus for tricuspid annular plane systolic excursion (TAPSE) and velocity measurements.^{60,61} Zooming the TV annulus for TAPSE is recommended. For laboratories with strain technology, these views can be optimized for RV longitudinal strain.^{58,59} At least two clips of these views are recommended (Table 2.16).

3. Apical Five-Chamber View. From the A4C view, the apical five-chamber view is obtained by tilting the ultrasound beam anteriorly until the LVOT, AV, and the proximal Asc Ao come into view.¹⁴ Examination in this view should focus on the LVOT, AV, and MV. A clip of this view should be recorded. Looking beyond the aortic outflow in this view, one might also see a part of the superior vena cava (SVC) entering the right atrium. Continued anterior tilting may demonstrate the RVOT and PV in some individuals.^{54,55} This RVOT view is not considered part of the normal examination (Tables 2.17a and 2.17b).

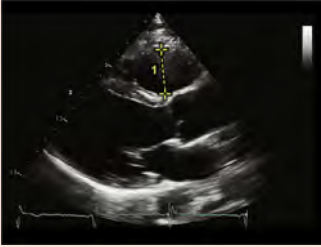


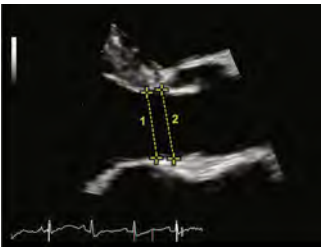
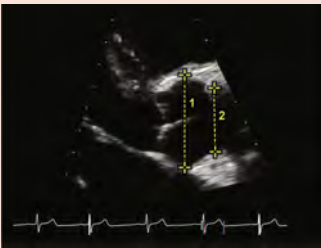
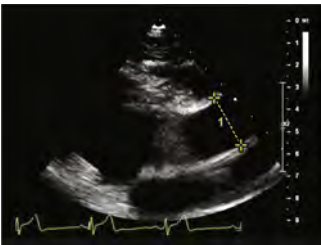
4. CS View. From the A4C view, the transducer is tilted posteriorly to image the CS,^{54,55} which appears as a tubelike structure replacing the MV between the left ventricle and left atrium. The sinus terminates near the junction of the septal leaflet of the TV and the right atrium. A membrane-like structure, the Thebesian valve, may be present at the junction of the CS with the right atrium. In this view, the Eustachian valve may be visualized in the right atrium, and the IVC may also be visible (Table 2.18).

Table 3 Two-dimensional linear measurements

View	2D grayscale linear measurements	Measurements to make
3.1. Parasternal window PLAX view		<ol style="list-style-type: none"> 1. IVS end-diastole thickness 2. LVIDd 3. LVPWd 4. RV diameter end-diastole
3.2a. Parasternal window Biplane imaging		<p>Biplane imaging can assist with proper perpendicular alignment for the most accurate 2D measurements.</p> <ol style="list-style-type: none"> 1. LVIDd is 47.0 mm
3.2b. Parasternal window Biplane view of axis from center of left ventricle		<p>Biplane imaging shows the consequence of off-axis measurements.</p> <ol style="list-style-type: none"> 1. The LVIDd is decreased by 3.0 mm from 47.0 mm (shown in 3.2a) to 44.0 mm
3.3. Parasternal window		<ol style="list-style-type: none"> 1. LVIDs
3.4a. Parasternal window PLAX view Sigmoid septum		<p>Measurement is moved slightly toward the LV apex just beyond the septal bulge.</p> <ol style="list-style-type: none"> 1. LVIDd is 53 mm 2. IVS is 7.0 mm
3.4b. Parasternal window PLAX view Sigmoid septum		<p>Measurement made at the MV leaflet tips, including the septal bulge.</p> <ol style="list-style-type: none"> 1. LVIDd is 38.0 mm 2. IVS is 17.0 mm

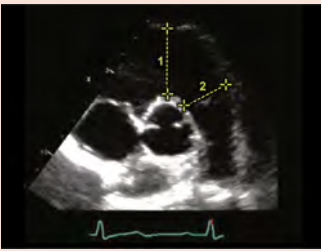

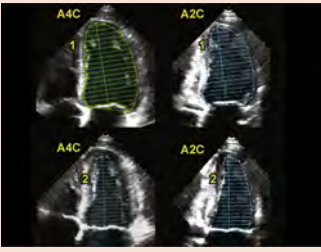
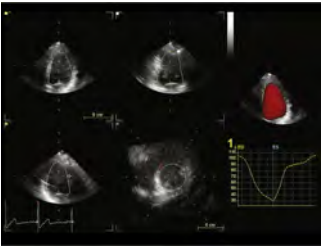

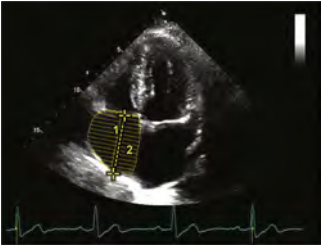
(Continued)

Table 3 (Continued)

View	2D grayscale linear measurements	Measurements to make
3.5. Parasternal window PLAX view		1. End-diastolic RVOT diameter
3.6. Parasternal window PLAX view		1. LA diameter
3.7. Parasternal window PLAX view Zoomed aortic annulus		Midsystolic measurement 1. AV annular diameter
3.8. Parasternal window PLAX view Zoomed LVOT		Midsystolic measurement 1. LVOT diameter 2. AV annular diameter
3.9. Parasternal window PLAX view Zoomed AoV and Asc Ao		1. SoVAo diameter 2. STJ diameter
3.10. Parasternal window PLAX view Asc Ao		1. Diameter of Asc Ao


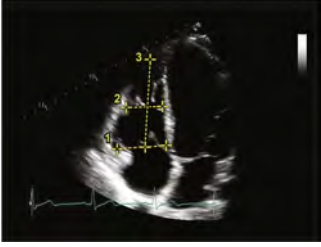
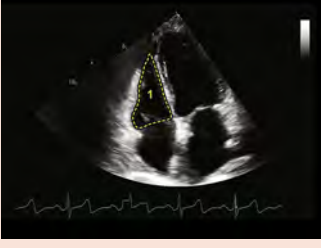

(Continued)

Table 3 (Continued)

View	2D grayscale linear measurements	Measurements to make
3.11. Parasternal window PSAX view AV level		1. End-diastolic RVOT proximal diameter 2. End-diastolic RVOT distal diameter Image reprinted with permission from Lang et al. (2015) ²
3.12. Parasternal window PSAX view Level of great vessels		1. Main PA diameter
3.13. Apical window A4C and A2C views Biplane disk summation		1. LV volume end-diastole 2. LV volume end-systole Image reprinted with permission from Lang et al. (2015) ²
3.14. Apical window 3D measurement example		1. LVEF calculated from 3D data set
3.15. Apical window 4C view Atrial volumes		1. LA length 2. LA area
		1. RA length 2. RA area

(Continued)

Table 3 (Continued)

View	2D grayscale linear measurements	Measurements to make
3.16. Apical window 2C view Atrial volume		1. LA length 2. LA area
3.17. Apical window 4C RV-focused A4C		1. RV base diameter 2. RV mid diameter 3. RV length
3.18. Apical window RV-focused A4C		1. RV area
3.19. SC window IVC view		1. IVC diameter

5. Two-Chamber View. From the full A4C view, the transducer is rotated approximately 60° counterclockwise to demonstrate the apical two-chamber (A2C) view.¹⁴ In this view, the left atrium, MV, and left ventricle are demonstrated. The CS can also be seen in short axis, positioned in the atrioventricular groove. Other structures that might be visible are the LA appendage along the right side of the sector and the left upper Pulvn. Two clips of this view should be obtained, one full-sector view (Table 2.19) showing the entire left ventricle and left atrium and a second focused view showing only the left ventricle (Table 2.20).

6. Apical Long-Axis View (Three-Chamber View). To obtain the apical long-axis view, commonly referred to as the three-chamber view, the transducer should be rotated counterclockwise 60° from the A2C view.¹⁴ The apical long-axis view demonstrates the left atrium, MV, left ventricle, AV, and aorta. As with the two-chamber view, two clips should be recorded: one full-sector view (Table 2.21) from apex to base of the left atrium and a second view focused on the left ventricle (Table 2.22).

7. A4C and A2C Views Demonstrating the Atria and Pulvns. From the standard A4C view, to optimize imaging of the atria, imaging depth should be increased to be able to see 2 cm behind the atria. This will allow imaging of the Pulvns entering the atria (Table 2.23). In addition, the focal zone (if available) can be placed at the level of the atrioventricular valves and/or just behind the atria, whichever demonstrates the anatomy most clearly. The overall gain and TGCs should be adjusted to optimize the B-mode image. A video clip is taken demonstrating the Pulvns entering the left atrium.

Frequently the maximal image of the left atrium is not in the same plane as the optimal LV image. The transducer should be separately positioned to optimize the view of the left atrium, to maximize the width of the base of the atrial chamber, followed by positioning to maximize the chamber long axis to avoid foreshortening. This view should be recorded and used for chamber quantification. Similarly, the transducer should be repositioned to obtain an optimal view of the right atrium to be used for quantification. Clips should be recorded specifically for quantification.

Moving back to the A2C view, the process should be repeated to obtain optimal data in the two-chamber view of the left atrium. With proper positioning, the left atrium in the A2C view should have a long-axis dimension within 5 mm of that obtained in the A4C view.

D. SC Window and Views

The SC window is used to assess the heart, pericardium, RV free wall thickness, and great vessels located in the abdomen (IVC and SVC, hepatic veins [Hvns], and abdominal aorta). It can be very useful for imaging the heart when the images are suboptimal from the parasternal window.^{2,14} The SC view is obtained with the patient laying supine with abdominal muscles relaxed. Having the patient bend his or her knees may help relax the stomach muscles, thereby making the views easier to obtain. The image may be further improved by acquiring it during held inspiration.

1. SC Four-Chamber View. SC imaging begins with the transducer placed on the patient's abdomen at the junction of the rib cage (xiphoid process), with the index marker pointed to the patient's left, at about a 3 o'clock position. The transducer is pointed toward the patient's left shoulder, transecting the heart in a four-chamber orientation. From this image, the right atrium, TV, left atrium, MV, left ventricle, interatrial septum, and interventricular septum can be examined.¹⁴ This view is particularly important to assess the interatrial and interventricular septa for defects, and the RV wall thickness, as the ultrasound beam is perpendicular to each septum. A video clip should be recorded (Table 2.24).

2. SC Short-Axis View. From the four-chamber view, counterclockwise rotation of the transducer approximately 90° should result in a short-axis orientation of the heart. The liver and IVC are imaged by maintaining the short-axis orientation of the heart and pointing the transducer toward the patient's liver (Table 2.25). The primary purpose of this view in the routine examination is to show the IVC in the longitudinal plane for several centimeters as it courses into the right atrium.² A video clip of a respiratory cycle should be obtained of the longitudinal IVC. This view is used to measure the diameter of the IVC and to evaluate IVC diameter changes during respiration (collapsibility index) to estimate central venous pressure.^{2,58} The Hvns draining into the IVC should also be imaged from this view and a clip acquired (Table 2.26).

E. SSN Long-Axis View

The patient is positioned supine with a pillow behind the shoulders so that the head can be tilted backward. Turning the patient's face leftward, the transducer is placed in the SSN, with the index facing 12 o'clock initially, with gradual clockwise rotation toward the left shoulder (1 o'clock), and tilted toward the plane that cuts through the right nipple and the tip of the left scapula (Table 2.27).^{14,55} The structures visualized are the aorta (ascending, transverse, and descending), and the origins of the innominate, left common carotid, and left subclavian arteries. The right PA is demonstrated in cross-section. Additional views from the SSN window are provided in the appendix.

V. TWO-DIMENSIONAL MEASUREMENTS

A. PLAX View

The PLAX view should be used for linear measurements of the left ventricle.

1. Left Ventricle. LV wall thicknesses and chamber dimension are measured at end-diastole, defined as the first video frame immediately after mitral leaflet closure.² If mitral motion is not visible, end-diastole may be identified as the peak of the R wave on the electrocardiogram. The image should demonstrate the chamber along its center axis to maximize dimension. Papillary muscles should not be visible in the PLAX view. An electronic caliper is positioned at the interface of the compacted myocardium of the interventricular septum and a line extended perpendicular to the long axis of the left ventricle to the inner border of the compacted myocardium of the posterior wall (Table 3.1). The measurement should be obtained at a level just below the MV leaflet tips.² The interventricular septum and LV posterior wall should be measured at the same time and level as the LV end-diastolic dimension. Only the compacted tissue of the septum should be included in the measurement, taking care to avoid including RV trabeculae, the insertion of the moderator band, or the TV apparatus as septal thickness.⁶² For measurement of the interventricular septum, the caliper should be placed at the interface where the RV cavity meets the compacted interventricular septum and moved to where the interventricular septum meets the LV cavity.² For measurement of the LV posterior wall, the caliper should be placed at the interface of the compacted posterior wall and LV cavity and moved to the LV posterior wall-pericardial interface.² Care must be taken to avoid including the MV apparatus in the measurement (Tables 3.2a and 3.2b). The cine loop should be advanced frame by frame to aid in differentiating posterior wall from leaflets and chordae tendineae. The LV end-systolic dimension should be obtained at the smallest cavity dimension, usually the frame preceding the initial early diastolic opening of the MV, just distal to the MV leaflet tips (Table 3.3).² An exception to this rule involves the presence of isolated thickening of the basal septum (sigmoid septum or septal bulge). In this case, the measurement location in systole and diastole should be moved slightly toward the LV apex to just beyond the septal bulge, making all linear measurements at this level.^{63,64} The measurements should remain perpendicular to the long axis of the ventricle (Table 3.4).

2. Proximal RVOT. The proximal RVOT should be measured in the PLAX view at end-diastole. The measurement caliper should be placed at the interface of the compacted anterior RV wall and the RV cavity and extended to the interface of the septal-aortic junction (Table 3.5).⁵⁸

3. Anterior to Posterior LA Measurements. Two-dimensional linear anterior-posterior measurements of the left atrium are preferred. M mode may also be used for this measurement. The left atrium is measured at end-systole using a leading edge-to-leading edge method.² For the 2D technique, the caliper is placed at the level of the SoVAo of the aortic root and extended to the leading edge of the posterior LA wall perpendicular to the assumed long axis of the atrial chamber (Table 3.6).² For M mode, the cursor is oriented perpendicular to the aortic root and left atrium, at the level of the aortic sinuses. The measurement caliper is positioned at the leading edge of the posterior wall of the aortic sinus and extended to the leading edge of the posterior LA wall (Table 4.1).²

4. LVOT and Aortic Annulus. The LVOT and aortic annular diameters are measured from zoomed PLAX images of the LVOT and AV. The image should be optimized to show the center axis of the LVOT with visualization of AV cusp insertion points (annulus). The aortic annular diameter is measured from the inner edge to inner edge of the

right and noncoronary leaflet insertion points at the maximal opening of the valve near midsystole (Table 3.7). For the LVOT diameter, using a similar inner edge-to-inner edge methodology, the measurement should be made approximately 3 to 10 mm from the valve plane in midsystole.^{35,37} The diameter interfaces are the compacted myocardium ventricular septum and anterior MV leaflet. The diameter measurement position should correspond to where the PW Doppler sample volume is placed for the LVOT Doppler tracing (Table 3.8).²

5. Asc Ao. Several measurements of the aorta are made from the PLAX view. All measurements are made perpendicular to the long axis of the vessel at the largest dimension, using a leading edge-to-leading technique at end-diastole.² The measurement of the SoVAo is taken at the maximum diameter of the sinus. The measurement of the sinotubular junction should be made at the junction of the distal sinuses and origin of the tubular aorta (Table 3.9). The tubular portion of the Asc Ao is measured at the largest dimension identified above the aortic sinuses.^{2,65} Moving to a higher parasternal window, closer to the sternum, and/or held expiration may be required to visualize the Asc Ao (Table 3.10).

B. PSAX View

1. RVOT. The proximal and distal RVOT are measured from the PSAX view that is positioned to show the AV at the level of the leaflets at end-diastole. A caliper is placed at the interface of the compacted myocardium anterior RV wall and RV cavity and a line extended to the blood-tissue interface of the aortic root. The distal RVOT should be measured using an inner edge-to-inner edge technique at end-diastole just proximal to the PV (Table 3.11).⁵⁸

2. PA. The main PA is measured midway between the PV and the PA bifurcation, using an inner edge-to-inner edge technique at end-diastole (Table 3.12).⁵⁸

C. Apical Views

1. LV Volume. Calculation of LV volumes and ejection fraction from linear measurements is not recommended and should not be reported.²

a. Biplane Disk Summation.—The biplane summation-of-disks method is the recommended 2D volume measurement technique. Apical views should be used with a reduced sector size that displays only the left ventricle, MV apparatus, and a small portion of the left atrium, to enhance definition of the chamber at a maximal frame rate. The LV apex should be centered in the sector and the long axis of the chamber maximized. Measurements for LV volume are made by tracing the LV cavity along the interface of the compacted and noncompacted myocardium of the chamber wall. These measurements are made in the apical four- and two-chamber views at end-diastole and end-systole, defined as the largest and smallest visible areas in each view, respectively. Papillary muscles and trabeculae are excluded from tracing and are considered to be part of the chamber. The tracing is completed by drawing a horizontal line across the left ventricle at the level of the MV annulus. From the center of this line, a vertical line is extended to the farthest point of the apex for calculation of the height of the disks.² The difference in LV lengths between the four- and two-chamber views should be <10%.² Several systems offer semiautomatic endocardial tracking algorithms to calculate volumes and ejection fractions. The systems should display endo-

cardial tracking throughout the cardiac cycle to allow evaluation of the quality of the data. Errors in tracking may be manually adjusted. These tracking loops should always be recorded to allow the interpreter of the study to judge the quality of the data. Similarly, the raw data of loops used for biplane summation tracings should always be recorded as part of the study. When endocardial definition is reduced, UEAs are highly recommended and can markedly enhance quantification (Table 3.13).²

b. Three-Dimensional LV Volume.—If available, use of 3D algorithms for LV volume and function assessment is preferred over the summation-of-disks method.^{2,57} All the techniques discussed above for optimization of the LV display are relevant to 3D imaging. It is important to position the left ventricle so that the entire chamber is captured in the volume set at as high a frame rate as possible. Several systems offer semiautomated algorithms for volumetric calculation and display. This technique potentially offers the best correlation of echocardiography-derived volumes to reference standards when image quality is excellent.⁶⁶

As with 2D techniques, full-disclosure displays of tracking and volume sets are necessary for the interpreter to judge the quality of the information (Table 3.14). Echocardiography laboratories are encouraged to establish standardized work flows for processing and reporting 3D data.

2. LA Volume. As noted above, 2D LA images should be independently obtained and optimized in preparation for volume quantification.² First, maximum volume at end-systole should be identified. LA endocardial borders in the A4C and A2C views should then be traced. The tracing of the left atrium is completed by drawing a line from one aspect of the annulus to the opposite side. The atrial appendage and Pulvns should not be included in this tracing. The length of the left atrium should be measured in both the A4C and A2C views. This length is measured from the center of the mitral annulus to the inner edge of the furthest extent of the traced superior LA wall, at the approximate midpoint. The long-axis lengths should be within 5 mm of each other. If they are not, the apical images should be reevaluated.⁶⁷ Most ultrasound systems automatically calculate LA biplane volume using both area-length and biplane disk summation. With the area-length method, the shorter length obtained (in the two- or four-chamber view) should be used for calculating LA volume.^{2,67} With the method of disks, the longer of the two lengths should be used. The method of disks is the preferred method for calculating LA volume, as it involves fewer assumptions regarding the shape of the left atrium (Tables 3.15 and 3.16).² Because volume calculation varies by technique, it is important that the laboratory consistently use the same technique.⁶⁸

3. RV Linear Dimensions. In the RV-focused A4C view, the RV linear longitudinal end-diastolic dimension is measured by drawing a line from the midpoint of the tricuspid annulus to the interface of compacted myocardium at the apex of the chamber. Diameter measurements include the maximum transverse diameter in the basal third of the right ventricle at end-diastole and the midcavity linear dimension midway between the maximal basal diameter and apex. The midcavity diameter measurement is made at the level of the papillary muscles at end-diastole (Table 3.17).^{2,58}

4. RV Area. In the RV-focused A4C view, RV area is measured by tracing the compacted muscle blood-endocardial tissue border

from the tricuspid annulus to the apex and back to the tricuspid annulus. Making this measurement at end-diastole and end-systole yields the fractional area change of the right ventricle.^{58,59} For RV measurements, the papillary muscles, trabeculations, and moderator band are included within the area measurement. For accurate measurements to be made, the view needs to demonstrate the entire right ventricle in a well-positioned RV-focused view (Table 3.18).

5. Right Atrial Volume. In the A4C view, a dedicated right atrial view should be obtained and optimized. At end-systole, an outline of the right atrial blood-tissue interface is traced, excluding the right atrial appendage, SVC, and IVC, to the level of the tricuspid annulus. A vertical line is extended from the midpoint of the TV annulus to the middle of the superior basal wall of the right atrium. The single-plane summation-of-disks method is used to calculate right atrial volume (Table 3.15).^{2,58,67}

D. SC Views

1. IVC. The IVC diameter is measured from the SC long-axis view, with the patient in the supine position. The measurement should be made 1 to 2 cm proximal to the junction of the IVC and right atrium.^{2,58} The IVC diameter should be measured at its maximum dimension, usually during expiration. A sufficiently long recording should be made to observe the change in IVC diameter during the respiratory cycle. If central venous pressure is normal, the diameter of the IVC typically collapses >50% of its expiration diameter. If not, or a less vigorous collapse is observed, the patient should be instructed to perform a rapid inspiratory “sniff” to force a more significant change in intrathoracic pressure and record IVC motion a second time. This information is taken together with the IVC diameter to estimate right atrial pressure.^{2,58} (Table 3.16).

Key Points #3

Measurements

- Linear measurements of the left ventricle should be made in the PLAX view with the ventricular chamber optimally centered and as perpendicular as possible to the long axis.
- Consistently make LV dimension measurements just beyond the leaflet tips of the MV. Pay careful attention to the posterior wall; avoid measuring mitral chordal and papillary muscle apparatus. Similarly, avoid including right-sided structures that insert into the septum when measuring septal thickness.
- If a basal septal bulge is present, move the dimension measurements slightly apical beyond the bulge.
- The anterior-posterior diameter of the left atrium may be measured using M-mode or 2D imaging as the diameter line extending from the SoVAo to the posterior wall of the left atrium. Two-dimensional imaging is preferred over the M-mode technique. Both measurement techniques should maintain a consistent orientation to these two structures.
- Diameters of the LVOT and aortic annulus are systolic measurements, and measurements of the aorta are diastolic measurements. The outflow tract diameter is

defined by the septum and anterior mitral leaflet, and the location in the outflow tract is defined by placement of the sample volume that achieves laminar flow just proximal to the AV.

- LA volume calculated from the A4C and A2C views adjusted to optimize display of the left atrium is the preferred method of atrial size quantification. The superior-inferior long axes from the two views should be within 5 mm of each other.
- RV dimensions and areas are preferably measured in the RV-focused view.
- M-mode techniques are not recommended for routine linear dimension measurements. Specialized measurements such as TAPSE, IVC diameter during respiration, and prolonged analysis of AV leaflet motion in patients with LV assist devices are valuable specialized measurements.
- LV volume and LV ejection fraction are preferably measured using 3D techniques. The size and depth of the acquired volume should be optimized to maximize frame rate. Tracking of the entire cardiac cycle should be reviewable and correctable and displayed as part of the final images acquired.
- If 3D volumetric analysis is not available, the 2D biplane method of disks is preferred for calculation of LV volume and LV ejection fraction.

VI. M-MODE MEASUREMENTS

Routine linear M-mode measurements for quantification are not recommended. The writing committee does recommend recording the standard PLAX views for the MV and the left ventricle, as unique diagnostic data that incorporate temporal events (e.g., MV motion, septal and posterior wall motion) that may be present (Tables 4.2 and 4.3). The LA anterior-posterior diameter, discussed in the section on LA measurement, and the two measurements noted below may still be used by some laboratories and in research imaging protocols.

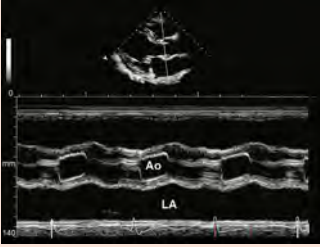
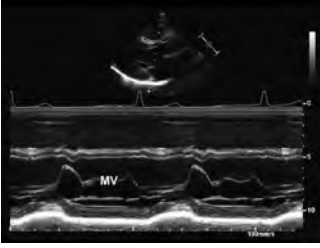
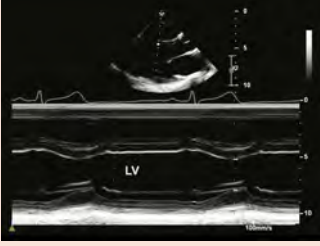
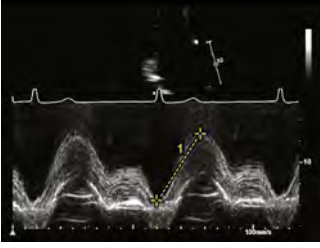

A. TAPSE

TAPSE is a measurement of longitudinal systolic performance of the right ventricle.^{60,61} It is measured in the A4C view.^{58,59} An M-mode cursor should be aligned along the RV free wall as perpendicular to the lateral tricuspid annulus as possible (and as parallel as possible to movement of the TV annulus). The TV annulus ROI should be demonstrated as large as possible without eliminating relational anatomic structures. The distance moved by the leading edge of the annulus from end-diastole toward the apex at end-systole is measured (Table 4.4).^{2,58,59}

B. IVC

M-mode imaging in the SC window is a method for measuring IVC diameter⁶⁹ and the IVC collapsibility index.⁷⁰ The M-mode cursor is placed through the IVC approximately 1.0 to 2.0 cm distal from the right atrium, and the IVC diameter is measured at rest and during normal respiration. It may also be measured with the patient performing a sniff maneuver. The collapsibility index can be calculated using the ratio of the diameters obtained.² Care should be taken

Table 4 M mode

View	M-mode image	Anatomy demonstrated
4.1. PLAX window		M mode through Ao and left atrium
4.2. PLAX window		M mode through MV
4.3. PLAX window		M mode through LV
4.4. A4C window Focused RV view		1. TAPSE
4.5. SC window IVC		IVC reactivity Arrow demonstrates patient sniffing maneuver

Ao, Aorta.

that the M-mode cursor transects the IVC in a perpendicular fashion so that the diameter is not erroneously overestimated. Imaging the IVC in short axis during the sniff maneuver can help determine if the IVC translates out of the imaging plane during inspiration (Table 4.5).

C. AV

There are instances in which M-mode imaging of the AV may be helpful for timing events and monitoring timing of valve opening and clos-

ing. A clinical example would be using M mode to measure the degree of AV opening in patients with LV assist devices.⁷¹

VII. COLOR DOPPLER IMAGING

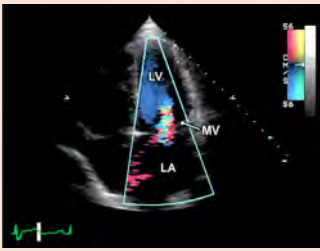
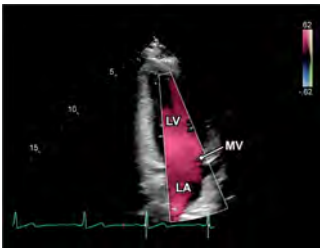

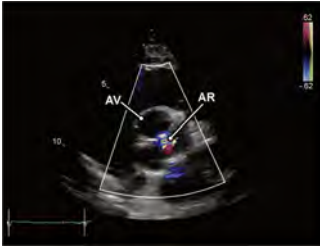


CDI is routinely used in virtually all imaging views and windows following 2D image acquisition. It is not an independent imaging technique. Therefore, all CDI must be interpreted in the context of

Table 5 Color Doppler images for protocol

View	2D TTE image	Structures to demonstrate
5.1. Parasternal window (see Video 69) PSAX view RVOT		Color Doppler RVOT PA
5.2. Parasternal window (see Video 70) PLAX view RV inflow		Color Doppler TV RA RV
5.3. Parasternal window (see Video 71) PLAX view RV inflow with TR		Color Doppler TV TR RA RV
5.4. Parasternal window (see Video 72) PSAX view (level great vessels) TV and RV inflow		Color Doppler TV RA RV
5.5. Parasternal window (see Video 73) PLAX view MV zoomed		Color Doppler MV LA LV
5.6. Parasternal window (see Video 74) PSAX view Level of MV		Color Doppler LV MV

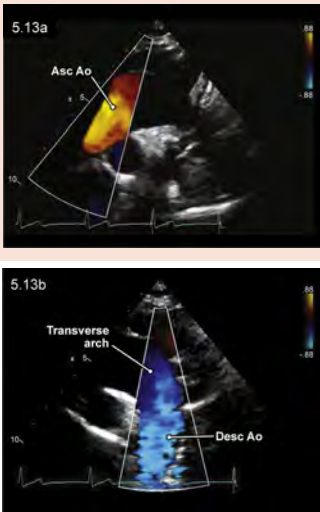
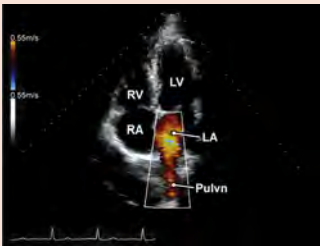
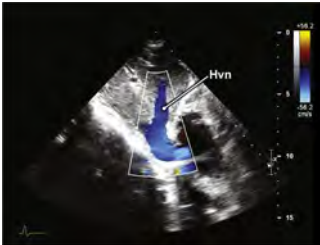

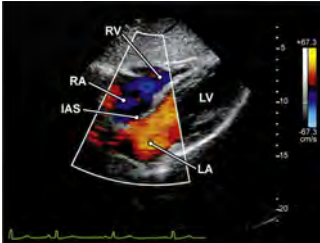
(Continued)

Table 5 (Continued)

View	2D TTE image	Structures to demonstrate
5.7. Apical window (see Video 75) A4C view		Color Doppler Left atrium MV LV
5.8. Apical window (see Video 76) A2C view		Color Doppler Left atrium MV LV
5.9. Parasternal window (see Video 77) PLAX view AV zoomed		Color Doppler AV LVOT Ao
5.10. Parasternal window (see Video 78) PSAX view AV leaflets		Color Doppler AV
5.11. Apical window (see Video 79) 5C view		Color Doppler LVOT LA LV AV RV
5.12. Apical window (see Video 80) 3C view		Color Doppler MV LV LVOT AV LA

(Continued)

Table 5 (Continued)

View	2D TTE image	Structures to demonstrate
5.13. SSN window (see Videos 81 and 82) Aortic arch	 <p>5.13a</p> <p>Asc Ao</p> <p>5.13b</p> <p>Transverse arch</p> <p>Desc Ao</p>	Color Doppler Asc Ao Transverse arch Desc Ao
5.14. Apical window (see Video 83) A4C view Pulvns	 <p>0.55m/s</p> <p>0.99m/s</p> <p>RV</p> <p>LV</p> <p>RA</p> <p>LA</p> <p>Pulvns</p>	Color Doppler Pulvns LA MV LV RV RA
5.15. SC window (see Video 84) IVC, Hvn	 <p>0.53.2</p> <p>0.18.2</p> <p>0.18</p> <p>0.15</p> <p>Hvn</p>	Color Doppler IVC Hvn
5.16. SC window (see Video 85) IVC view	 <p>0.27</p> <p>0.27</p> <p>IVC</p>	Color Doppler in the IVC
5.17. SC window (see Video 86) 4C view	 <p>0.67.3</p> <p>0.5</p> <p>0.10</p> <p>0.15</p> <p>0.20</p> <p>RV</p> <p>RA</p> <p>IAS</p> <p>LV</p> <p>LA</p>	Color Doppler RA RV LA LV IAS

For Videos 69 to 86, see www.onlinejase.com.

the M-mode, 2D, or 3D image with which it is combined. It is recommended that the anatomic image be recorded first, immediately followed by the CDI examination. For routine normal flow, one CDI interrogation is adequate. For unusual or eccentric flow signals, multiple views, sweeps, and off-axis images are recommended to fully characterize the pathology. If needed, the sector width can be narrowed to improve frame rate, but the sector should not be so narrow that parts of the ROI are eliminated. Simultaneous dual-screen side-by-side imaging showing the grayscale image on one side with CDI on the other can be helpful in select circumstances as an added view but is not recommended as the only color display for entire protocols. Rarely are both images optimal simultaneously, and data from either CDI or grayscale views may be missed. Similarly, routine protocols only showing CDI without an associated regular grayscale image are not appropriate. Although time is saved, crucial data are lost.

A. RVOT, PV, and PA

CDI should be used to interrogate the RVOT, PV, PA, and branch pulmonary arteries to assess for systolic flow, valve regurgitation, and shunts.^{37,43} These structures are evaluated in the PLAX, PSAX, and SC views. CDI scale settings should be set to 50 to 70 cm/sec but may need to be lowered for low-flow states (Table 5.1).

B. RV Inflow and TV

The TV can be interrogated using CDI from the PLAX RV inflow view, the PSAX TV view (level of aorta), the A4C view, an apical RV-focused view, and SC views. In each view, both forward flow and valvular regurgitation are assessed. The normal color-flow velocity scale (50–70 cm/sec) is used initially, particularly if TV regurgitation is noted. Velocity scale and gain may need to be optimized to demonstrate low-velocity forward flow. Off-axis planes should be used to fully characterize regurgitant jets (Tables 5.2–5.4).^{37,43} CDI should also be used to guide placement of the PW and CW cursors to align the Doppler sample as parallel as possible to flow.

C. LV Inflow and MV

The MV should be interrogated using CDI from the PLAX view, the PSAX view, and the A4C, A2C, and long-axis views. SC views may be used as necessary. To best demonstrate color Doppler velocities through the MV into the left ventricle, the valve should be positioned in the center of the sector to ensure that the entire valve is included in the color box, then the transducer rocked and angled through the valve to identify any stenotic or regurgitant jets. Depending on initial findings, additional CDI cine loops should be recorded to fully display the entire extent of inflow and regurgitation. Standard velocity scale settings combined with optimized CDI gain will best demonstrate flow. Forward flow is best demonstrated in the A4C view, which is most parallel to inflow. However, it should be realized that MV inflow is normally partially directed toward the lateral wall of the left ventricle. Regurgitant jets should be carefully mapped and may change markedly across different imaging planes (Tables 5.5–5.8).^{37,43}

D. LVOT and AV

The LVOT and AV are evaluated by pairing the grayscale views with CDI in the PLAX, PSAX, apical five-chamber, and apical long-axis views. The AV is interrogated to evaluate for laminar versus turbulent forward flow in systole and for turbulent regurgitant flow patterns in diastole. In each view, the color box width and length should be adjusted to initially display both the LVOT and AV. Careful attention should be paid to

panning through the valve in the multiple views to maximize detection of regurgitation. If turbulence is noted proximal to the valve in the LVOT, additional zoomed views may be needed to characterize the location of abnormal flow. CDI combined with M-mode imaging may be of considerable value to characterize timing of events in the LVOT. Color gain settings may need to be adjusted multiple times for different types of flow jets. Standard velocity scale settings should be initiated and adjusted for specialized measurements as needed (Tables 5.9–5.12).^{37,43}

E. Aortic Arch

When imaging the arch, the color box needs to be aligned with the segment of interest, and the operator will need to manipulate the transducer to demonstrate the Asc Ao, transverse arch, and descending aorta (Desc Ao) at the best Doppler angle to demonstrate color fill. Because the aorta is close to the transducer, some systems may automatically raise the Nyquist limit to very high levels and may need to be adjusted downward to achieve good color fill. Marked changes in color hue are normally expected, from red hues of flow toward the transducer in the Asc Ao, to black at the top of the arch due to virtual perpendicular orientation to flow, to blue hues of flow away from the transducer in the Desc Ao (Tables 5.13a and 5.13b).^{37,43}

F. Pulvns

The Pulvns should be interrogated with color Doppler in the A4C view. This plane is most parallel to flow and typically exhibits three of the four Pulvns. Anterior angulation toward the apical five-chamber view may demonstrate the fourth Pulvn, the right upper Pulvn. The depth should be set to allow visualization of the Pulvns entering the left atrium. The color box ROI should be set as small as possible to maintain higher frame rates. Because of the imaging depth and lower flow velocities, the color gain will need to be calibrated and the Nyquist limit reduced to demonstrate good color filling (Table 5.14).³ CDI can also assist with identification of which Pulvn is being imaged on the basis of the color map (red toward, blue away).

G. Hvnns

The Hvnns are imaged from the SC window.¹⁴ Color-flow Doppler is often set to image the middle Hvn, as it often is the one that lies at the best Doppler angle. The color Doppler ROI should be set to demonstrate blood flow in the Hvnns as they enter the IVC. Color-flow Doppler may be optimized by adjusting the gain and setting the velocity scale to a lower range to demonstrate the best color fill without color aliasing and noise (Table 5.15).

H. IVC

In the SC long-axis view of the IVC, if practicable, the IVC should be imaged at an angle of $\leq 60^\circ$ to best demonstrate color. The color velocity scale settings should be reduced and the gains adjusted to demonstrate good color fill in the IVC. The entire length of the visible IVC should be interrogated with CDI (Table 5.16).

I. Atrial Septum

The atrial septum can be visualized from the A4C, PSAX, and SC views.⁵⁴ The depth can be adjusted or the zoom box used to display the right atrium, interatrial septum, and left atrium as large as possible without eliminating any of these structures of interest. CDI is optimized at a lower velocity scale and gains adjusted. The entire length of the atrial septum should be included, looking for any evidence of color crossing the septum in all views. The jets may be eccentric. The SC view is most effective

because grayscale images are close to perpendicular to the ultrasound beam and most flow signals from a septal defect are parallel (Table 5.17).

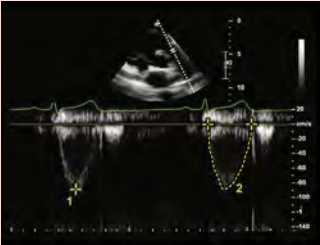
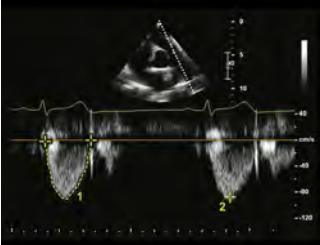
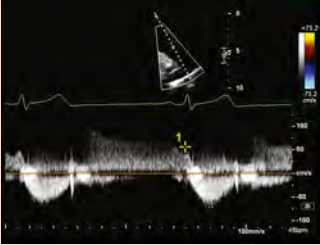
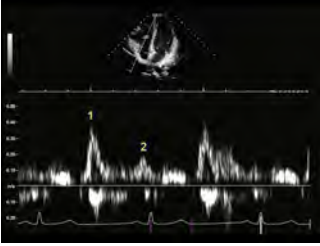
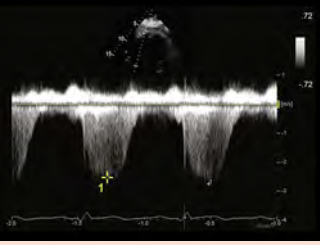
VIII. SPECTRAL DOPPLER IMAGING MEASUREMENTS

This section will discuss the routine Doppler measurements performed during a complete TTE examination. Laboratories should establish standards for those measurements that are to be made. Clinical circumstances may dictate variations in the number of beats measured.

Measurements should be taken from the recorded video clips and saved as separate still frames. This will allow Doppler measurements to be made at the time of acquisition or by the interpreting physician.

The section is organized by valve. CDI should be used to help align the spectral Doppler cursor as parallel to blood flow as possible, and a sweep speed of 100 mm/sec should be used. The baseline and pulse repetition frequency/scale settings must be individually optimized for each valve and velocity measurement to demonstrate the best quality signal without aliasing.

Table 6 Spectral Doppler images for protocol

View	Spectral Doppler	Measurements to Make
6.1. Parasternal window PSAX view RVOT		PW Doppler in RVOT 1. Peak RVOT velocity 2. RVOT VTI
6.2. Parasternal window PSAX view Great vessel level		CW Doppler in RVOT 1. PV VTI 2. Peak PV velocity
6.3. Parasternal window PSAX view RVOT		CW Doppler in RVOT 1. End-diastolic PR velocity
6.4. Apical window A4C view TV inflow		PW Doppler in TV 1. E measurement TV inflow 2. A measurement TV inflow
6.5. Parasternal window PLAX view TV zoomed		CW Doppler TR 1. Peak velocity

(Continued)

Table 6 (Continued)

View	Spectral Doppler	Measurements to Make
6.6a. Apical window A4C view		PW Doppler of MV 1. E-wave velocity 2. Deceleration slope 3. Deceleration time 4. A-wave velocity
6.6b. Apical window A4C view		Change in flow pattern with Valsalva
6.7a. Apical window A4C view		CW Doppler MS 1. MS VTI to measure mean gradient
6.7b. Apical window A4C view		2. MS pressure half-time measurement
6.8. Apical window CW Doppler of MV regurgitation		CW Doppler of MV regurgitation 1. VTI 2. Peak velocity
6.9. Apical window A4C view		PW Doppler of MV flow effect of tachycardia MV inflow, tachycardia 1. MV deceleration time interrupted

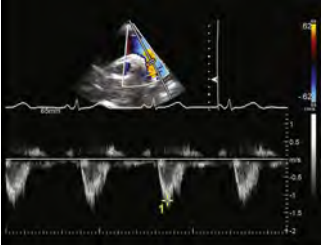
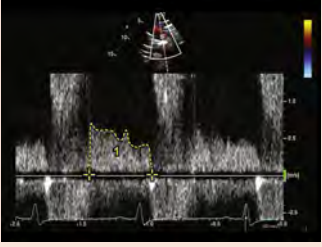
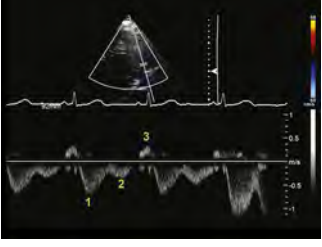
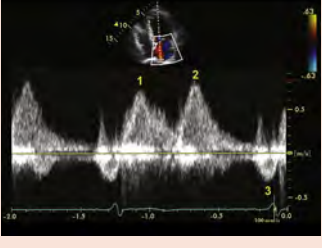
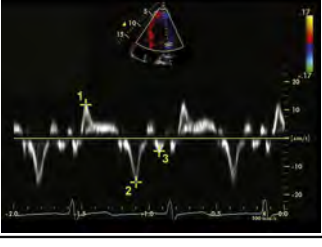
(Continued)

Table 6 (Continued)

View	Spectral Doppler	Measurements to Make
6.10a. Apical window 5C view		PW of LVOT 1. LVOT VTI 2. LVOT peak velocity
6.10b. Apical window 5C view		HPRF PW of LVOT Doppler 1. LVOT peak velocity
6.10c. Apical window 5C view		LVOT CW Doppler 1. LVOT maximum flow velocity
6.11. Apical window 5C view		Apical window CW Doppler directed through the AV 1. AV VTI 2. Peak AV velocity
6.12. Apical window 5C view		CW Doppler 1. AR peak velocity (used in quantitative techniques to calculate proximal isovelocity surface area) 2. AR slope (used to calculate pressure half-time)
6.13a. SSN window		PW Doppler of Asc Ao 1. Peak systolic velocity

(Continued)

Table 6 (Continued)

View	Spectral Doppler	Measurements to Make
6.13b. SSN window		PW Doppler of Desc Ao flow 1. Peak systolic velocity
6.14. SSN window		PW Doppler of Desc Ao flow in patient with aortic regurgitation showing diastolic flow reversal 1. VTI AR
6.15. SC window		PW Doppler of Hvn flow 1. S wave 2. D wave 3. A wave
6.16. Apical window A4C view		Pulvn flow 1. S wave 2. D wave 3. A wave
6.17. Apical window A4C view		DTI MV lateral annulus 1. s' 2. e' 3. a'

Doppler imaging is directionally limited. The maximum Doppler shift is detected when the ultrasound beam is parallel to flow. Maximum detected velocity is reduced by a function of the cosine of the angle away from parallel. Fortunately, an angle of 20° results in only a 6% reduction in measured flow velocity, so keeping the interrogation reasonably close to parallel does not materially affect results. By first using color Doppler interrogation, alignment can be improved, but this cannot account for flow in all three dimensions. Ultrasound systems have angle correction algorithms, but this is not recommended for echocardiography. Instead, all valves and other areas of flow should be interrogated with multiple imaging planes. Data should only be used clinically from the imaging

plane producing the maximum velocity. Information from other planes must be edited out and not averaged.

During laminar flow, the modal velocity is the densest part of the flow signal, representing the majority of blood flow. This is the correct part of the signal to trace or measure a peak velocity.^{2,37,43} An overgained signal may obscure the modal velocity. For turbulent flow, a distinct border should be identified that best represents the flow signal. Excessive gain may obscure this border, while undergained flow may miss the maximum velocity. The laboratory should agree on standardized presets for routine imaging and a set of alternatives for nonstandard situations. All operators should be aware of these settings and their proper use.

A. RVOT and PV

Forward flow through the RVOT should be evaluated in the PLAX or PSAX view. The view that provides the Doppler angle most parallel to flow is preferred. To begin, the PW Doppler sample volume (4–5 mm) should be positioned in the center of the RVOT, about 5–10 mm proximal to the PV. The normal forward velocity waveform is downward and systolic. A short vertical spike (closing click) may be present and suggests appropriate positioning of the sample volume. The RVOT peak velocity and VTI are measured (Table 6.1). The RVOT acceleration time and RV ejection time are additional optional measurements from this velocity waveform.

For the PV, a CW Doppler cursor should be oriented as parallel as possible to the flow across the valve. The outer edge of the modal velocity signal should be traced to obtain the VTI (Table 6.2). The PV peak systolic velocity is measured from the same signal by placing the cursor at the peak of the spectral profile.⁷²

If pulmonary regurgitation is present, it should be displayed with CW Doppler (Table 6.3). The user should position the CW Doppler cursor parallel to the flow of the regurgitant jet, displaying the full diastolic flow signal. Measurement of end-diastolic velocity is possible using an electronic caliper (Table 6.3).^{43,73,74}

B. TV

Forward flow velocity across the TV should be recorded through at least one respiratory cycle with PW Doppler. The normal flow is diastolic with two distinct waves: the first in early diastole (E velocity) and the second at the time of atrial contraction (A velocity). The velocity is best measured in the A4C view or RV-focused view, whichever one provides the best Doppler angle (Table 6.4). Using PW Doppler, a 1- to 3-mm sample volume should be positioned at the tips of the open valve leaflets in diastole. Although the flow velocity pattern should always be recorded, measuring and reporting peak velocities across the TV is not considered a routine measurement. Echocardiography laboratories should determine if this measurement is part of normal workflow or only to be measured under certain conditions. Given the significant normal variation in flow with respiration, echocardiography laboratories must also decide on how to make the measurement. Current guidelines suggest a measurement either at end-expiration or averaged across an entire respiratory cycle.^{30,58}

If TV regurgitation is present, CW Doppler should be used to obtain the peak tricuspid regurgitant velocity for assessment of RV systolic pressure.^{30,43,58} The maximum tricuspid regurgitant jet is variable and may be obtained from the PLAX, PSAX, A4C, apical RV-focused, or SC four-chamber view. In some cases, a weak flow signal may be enhanced using UEAs. If after the use of contrast agents the signal is still weak and/or incomplete, the measurement should not be reported. In addition, there may be substantial variation in flow velocity in different views. The highest velocity and view from a good-quality signal should be reported for the final calculation, and lower velocity data from other views should be edited out (Table 6.5).^{43,58}

C. MV

Spectral Doppler is used to characterize the patterns of forward diastolic flow across the MV and to measure several indices of mitral regurgitation, if present. In the A4C view, a 1- to 3-mm sample volume should be positioned at the tips of the open MV leaflets for PW Doppler recording. The sample volume should be placed toward the lateral wall, as blood normally flows across the valve in this direction. The peak E (early diastolic) and A (atrial contraction) velocities and MV early diastolic deceleration time should be recorded and

measured (Table 6.6a).³ The deceleration time is measured by placing a caliper on the peak E velocity and following the slope of the E wave to the baseline (Table 6.6a). An optional measurement is the A-wave duration, which is measured from the onset to the offset of the A-wave flow signal, with the measurement taken with the sample volume positioned in the flow at the level of the MV annulus.

If the MV appears abnormal, is a prosthetic valve, has been repaired, or shows flow velocities that are increased or turbulent by CDI or PW Doppler, CW Doppler should be used to measure the mean gradient and pressure half-time (Tables 6.7a and 6.7b).^{3,30,37,43,75}

Transiently lowering preload by recording MV flow during a Valsalva maneuver is a technique all operators should understand and be capable of performing. Every echocardiography laboratory should have a protocol for performance and a work flow to determine when the maneuver is indicated. The patient should be instructed to bear down against a closed glottis and practice this technique before recording. The sample volume is positioned in the same location as for normal MV flow recording. The MV inflow signal should be recorded for 10 to 12 sec before release. The recorded still image should be annotated to indicate the use of the Valsalva maneuver. The MV flow signal should change during the Valsalva strain. The E velocity should decrease by 20 cm/sec or $\geq 10\%$ if the strain is to be considered adequate. In normal patients, there is typically a relatively equal reduction in E and A velocities (Table 6.6b). In patients with elevated LA pressure and a pseudonormal filling pattern, the E velocity decreases to a greater degree than the A velocity, resulting in a reduction in the E/A ratio.⁷⁶

If mitral regurgitation is present, CW Doppler should be used to record the regurgitant flow in the A4C, A2C, and long-axis views. The flow signal should be traced along its modal margin to calculate a VTI, peak velocity, and peak gradient (Table 6.8).^{3,43}

In patients with tachycardia or some forms of heart block, there may be fusion of the E and A waves. This is best demonstrated by observing the E-wave velocity at the time of onset of the A wave. Significant fusion is present if the beginning of the A wave starts on the E deceleration slope line at an E velocity of >20 cm/sec. In this setting of fusion, the deceleration time should not be measured, the E/A ratio is decreased, and the A-wave velocity increased (Table 6.9).^{3,30,43}

D. LVOT and AV

The LVOT is best evaluated in the apical five-chamber or apical long-axis views. PW Doppler is used to obtain velocity in the LVOT. The PW Doppler sample volume is placed about 5 mm proximal to the AV in the center of the LVOT. The spectral signal should be narrow, with a rapid upstroke and an end-systolic click terminating the flow signal.^{30,37} Broadening of the flow signal indicates that the sample volume is too close to the AV and should be repositioned. The peak velocity should be measured and the signal traced to calculate a VTI (Table 6.10a). If high velocities or turbulent flow is present, CDI of the LVOT and left ventricle should be examined. Further abnormality (i.e., presence of AV stenosis) should prompt pulsed-Doppler mapping from the LV apex to the AV, noting the level at which high velocities are detected. If aliasing is present, a switch to HPRF Doppler can be considered to further evaluate flow velocities and the shape of the flow signal (Table 6.10b).^{3,30,37} The LVOT diameter should be measured at the same location at which the highest velocity signal was obtained.

After sampling the LVOT, CW Doppler is used to measure the aortic velocity.³⁷ The Doppler signal should be traced to provide a

peak velocity, peak gradient, mean gradient, and VTI. The distinct flow signal border should be traced, and weak, shaggy, low-amplitude clutter should not be included in the VTI tracing (Table 6.11). If aortic stenosis is suspected, a prosthetic valve is present, or high-velocity lesions are suspected in the LVOT, the nonimaging transducer should be used to acquire Doppler signals from the apical, right parasternal, and SSN windows.³⁷ In difficult patients, to assist with placement of the nonimaging CW Doppler transducer, a duplex imaging transducer should be used first and its position noted (Appendix Table 12.10: high right parasternal view of the aorta).

If aortic regurgitation is present, CW Doppler should be used to measure the peak velocity and pressure half-time. Color Doppler is used to direct the CW interrogation, as the regurgitant jet is frequently eccentric (Table 6.12).⁴³

E. Aortic Arch and Desc Ao

CW Doppler may be used to evaluate the Desc Ao for the presence of flow-limiting obstructions. PW Doppler can be used to sample multiple positions in the Asc Ao, transverse aortic arch, and Desc Ao (Tables 6.13a and 6.13b). This is done to evaluate any aortic pathology and to better define the location of obstructive lesions, such as coarctation of the aorta. Color Doppler can be used to guide the placement of the sample volume in interrogation of obstructive lesions. PW Doppler evaluation of the proximal Desc Ao can also be used to evaluate for diastolic reversal of flow associated with aortic regurgitation, rupture of the SoVAo, noncompliant aorta in elderly patients, arteriovenous fistula in the upper extremity, and aortic dissection (Table 6.14).^{37,43} Routine flow sampling should be performed in the proximal Desc Ao 10 mm below the origin of the left subclavian artery using a 3- to 5-mm sample volume. The normal PW Doppler signal is systolic and nonturbulent. In normal individuals, there typically is a brief low-velocity, early diastolic flow reversal. Reversal velocities longer than the first third of diastole are abnormal and associated with aortic regurgitation (Table 6.14).^{37,43}

F. Hvnns

Hvn flow is a three-component signal consisting of the S wave of flow into the IVC during systole, the D wave of flow into the IVC during the first part of diastole, and the A wave of flow reversal in the Hvn caused by atrial contraction.³⁰ Some patients have a fourth component: a brief ventricular flow reversal wave immediately following the S wave. A sample volume of 3 to 5 mm is placed in the Hvn about 1 to 2 cm from the junction with the IVC. Flow is recorded at this site and should be assessed during an entire respiratory cycle. Although absolute peak velocity measurements are not routinely recorded, the pattern of flow is a valuable diagnostic tool.^{30,33} If performed, peak S- and D-wave velocities should be measured at end-expiration (Table 6.15).

G. Pulvns

Inflow from the Pulvns to the left atrium is best imaged from the A4C or apical five-chamber view.⁷⁷ Typically, the right upper Pulvn, or at times the right lower Pulvn, has flow almost parallel to the Doppler cursor. A 3- to 5-mm sample volume should be placed about 10 mm proximal to the vein's junction with the left atrium. Color Doppler aids in the positioning of the sample volume.³ The flow signal is typically triphasic, with an S wave (during ventricular systole), D wave (during early diastole), and A reversal wave (during atrial

contraction). The inflow should be recorded in all patients (Table 6.16).³ The pattern of the inflow signal is important in several diagnostic settings. Actual peak velocity measurements of each wave are not part of a routine examination but may be measured and the duration of the A wave measured for comparison with the MV A-wave duration in some circumstances.³

H. Tissue Doppler of the Mitral and Tricuspid Annuli

Tissue Doppler is used to record velocities of the longitudinal movement of the lateral and medial mitral annulus as well as the lateral tricuspid annulus.^{3,16,38,39,58,59} The angle of interrogation should be as parallel as possible to the Doppler beam. DTI presets are markedly different from conventional PW Doppler settings and vary by manufacturer. It is best to have a system-specific preset for these measures. Tissue Doppler signals should be optimized by using a large sample volume of 5 to 10 mm to fully capture annular motion, and the scale should be set at ≤ 25 cm/sec depending on the actual velocity.^{3,16} To improve visualization of the peak annular velocities, decrease the velocity scale to maximize Doppler signal display¹⁶ and set the sweep speed at 100 mm/sec. Velocity waveforms are designated as s' for systole, e' for early diastole, and a' for atrial contraction. Accurate measurement is important, as both absolute velocities and the ratio of mitral E velocity to e' velocity are major parts of diagnostic criteria for noninvasive estimation of LV filling pressure and diastolic performance.^{3,16} Provision should be made to average the peak lateral and medial velocities of all three components and to report these values. The averaged e' is used for calculation of the E/ e' ratio in addition to individual data from the lateral and medial sites. Similar protocols are used for the lateral tricuspid annulus.^{58,59} The most important measurement for the right heart is the s' velocity, which correlates well with alternative measures of global RV systolic function (Table 6.17).⁵⁸

Key Points #4

Doppler Imaging and Measurements

- For routine CDI of valvular insufficiency and forward flow, use a consistent scale setting of 50 to 70 cm/sec. Maintain optimal gain settings.
- CDI scale velocity should be adjusted for specialized circumstances to best display color flow, particularly in low-flow states.
- Spectral PW and CW Doppler measurements should be made at the modal (densest) margin of the flow signal. Do not overgain. Do not measure weak, ill-defined signals beyond the modal velocity.
- Obtain spectral Doppler signals as parallel as possible to flow. CDI interrogation may help orientation.
- Flow signals may be acquired (e.g., tricuspid regurgitation) from multiple anatomic sites. Use the highest quality and highest velocity signals for final measurements. Edit out velocity data from poor-quality and lower velocity signals for the final reported velocity. Do not report Doppler flow signals of poor definition or marginal quality.
- Use CDI and pulsed Doppler mapping to characterize the origin of unusual signals within chambers or blood vessels.

- When recording spectral Doppler for measurements of velocity and time intervals, use a default sweep speed of 100 mm/sec. Slower sweep speeds are valuable for specialized pathology.
- For tissue Doppler, always maximize the signal display and use manufacturer-recommended presets.

IX. ADDITIONAL TECHNIQUES

A. Agitated-Saline Imaging

Agitated saline (a “bubble study”) is used to evaluate for interatrial shunts, such as a patent foramen ovale or atrial septal defect, and for intrapulmonary shunting, which may be due to pulmonary arteriovenous malformations or hepatopulmonary syndrome (Tables 7.1–7.4).⁷⁸ Agitated saline is also used if there is a question of the presence of a persistent left SVC (Table 7.5). Although the use of agitated-saline imaging is not a routine procedure for all TTE studies, an echocardiography laboratory should be provisioned with supplies and appropriate personnel to perform the procedure on demand during a routine study. Intravenous access is required. Imaging windows that provide the best view of the interatrial septum are used when assessing for an interatrial or intrapulmonary shunt. The A4C view is preferred to avoid shadowing of the left heart. If apical windows are of poor quality, the SC four-chamber view may be used (Table 7.4).

When performing a bubble study, it is important to time interaction of the video clip with the administration of the saline to determine how many heartbeats elapse before visualizing the saline bubbles entering the left atrium. Determining the timing of when bubbles enter the left atrium is helpful for differentiating between an intracardiac shunt and an extracardiac pulmonary arteriovenous shunt. The appearance of bubbles within three to six beats after full right atrial

opacification is considered positive evidence for an intracardiac shunt. Clip length must be prolonged to start with a right atrium free of bubbles, then show inflow of saline bubbles into the right atrium and possible early or late flow into the left atrium via either an intracardiac shunt or intrapulmonary shunt. Visualization of saline entering the left atrium via the Pulvns is an echocardiographic finding that is suggestive of transpulmonic shunting and should be evaluated when the Pulvns can be seen entering into the left atrium.⁷⁸ At least 20 consecutive beats should be recorded. Tissue harmonic imaging should be used to improve bubble visualization (Tables 7.1 and 7.3).

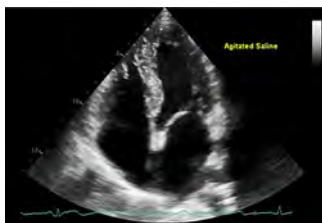Two 10-mL syringes and a three-way stopcock are needed for administration of saline. Syringes and stopcocks should be lockable, as the pressure resulting from either the agitation or injection of the saline-air mixture can cause pressure-fitted syringes and stopcocks to become disconnected, resulting in the agitated solution being sprayed on the administering staff member, operator, and patient. Eight to 10 mL of saline and ≤ 0.5 mL of air should be drawn into one syringe.⁷⁹ The air-saline mixture is briskly agitated between syringes and rapidly injected through a forearm or hand vein.⁷⁹ Care should be taken to ensure that the agitation is complete so that no large bubbles are injected.⁸⁰ If no shunt is noted, the injection should be repeated. Specific maneuvers that are used to transiently increase right atrial pressures, such as coughing, the Valsalva maneuver, and abdominal compression, may help elicit a right-to-left shunt if no shunt is detected during quiet respiration. When performing the Valsalva maneuver, the patient should be instructed to release when contrast arrives in the right atrium. Additional mechanisms to improve the detection of a shunt are shown in Table 7.2. The reader is referred to detailed guidelines on evaluation of the interatrial septum for more information.⁷⁸ Contraindications for use of agitated saline include known significant right-to-left shunts and pregnancy.

B. UEA Imaging

Guidelines for the use of UEAs are published and widely accepted.^{79,81,82} It is beyond the scope of this document to


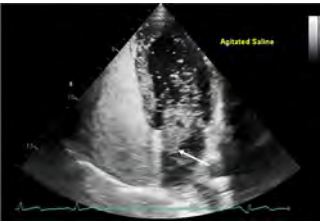
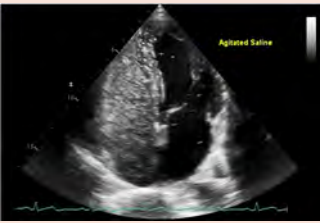
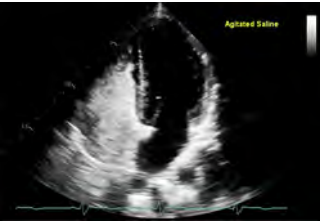
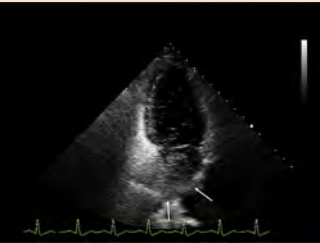
Table 7 Agitated saline information

2D TTE image	Information
Apical window A4C view	Structures to demonstrate <ul style="list-style-type: none"> • RA • RV • LA • LV • IAS
7.1a (see Video 87)	Complete 20-beat clip of a positive bubble study for PFO Optimally vertically aligned A4C view Initial beats without contrast



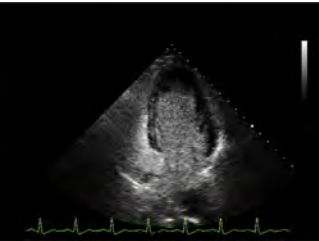
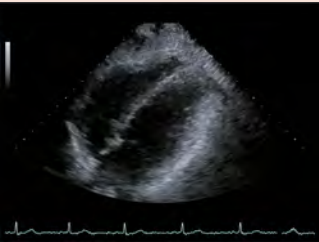
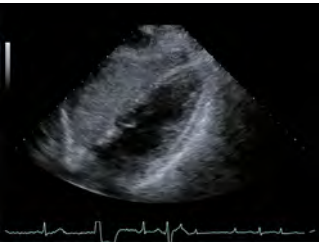


(Continued)

Table 7 (Continued)

2D TTE image	Information
<p>7.1b (see Video 87)</p> 	<p>Beat 1: full-contrast opacification Begin counting beats when initial full opacification of RA and RV is demonstrated An atrial septum aneurysm bowing leftward (arrow) is also noted</p>
<p>7.1c (see Video 87)</p> 	<p>Beat 4: bubbles originating at the atrial septum (arrow) within the first six beats following full opacification of the right side This demonstrates a bubble study positive for an intracardiac right-to-left shunt</p>
<p>7.1d (see Video 87)</p> 	<p>Beat 16 Demonstrates clearing of LA and LV as the bubble bolus completes its passage through the RA and RV This is consistent with no extracardiac shunt</p>
<p>7.2 (see Video 88)</p> 	<p>Complete 20-beat clip for a negative bubble study for PFO Additional maneuvers to try if conventional bubble injection is negative</p> <ul style="list-style-type: none"> • Add 1 mL blood to 1 mL air and 8 mL saline • Use cough, Valsalva maneuver, and/or abdominal compression-release when saline enters the right atrium; These maneuvers increase RA pressure relative to LA pressure • Use femoral vein injection instead of arm injection whenever streaming of inflow does not allow full opacification of the right atrium; the IVC flow is directed toward the right atrium and therefore may enhance the visualization of agitated saline crossing the septum
<p>7.3a (see Video 89)</p> 	<p>Complete 20-beat clip showing late appearance of bubbles in the LA and LV consistent with an extracardiac transpulmonary shunt Beat 9 demonstrating bubbles entering the left atrium via the Pulvns (arrows)</p>

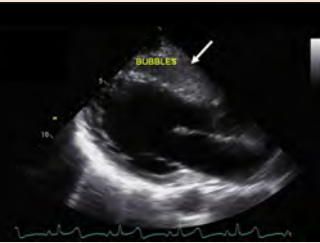
(Continued)

Table 7 (Continued)

2D TTE image	Information
<p>7.3b (see Video 89)</p> 	<p>Beat 16 demonstrating complete filling of the LA and LV with bubbles; note presence of bubbles in the Pulvns and dilution of bubbles in the RA and RV</p>
<p>7.4a</p> 	<p>Alternative imaging SC window 4C view Structures to demonstrate RA RV LA LV IAS Beat 1: no bubbles present</p>
<p>7.4b</p> 	<p>This view may be less sensitive for detecting right-to-left shunt because of shadowing from RV bubbles</p>
<p>7.5a (see Video 90)</p> 	<p>Imaging for a persistent left SVC, left arm injection Parasternal window PLAX view Structures to demonstrate LA MV LV CS (arrow) LVOT AV Asc Ao Imaging of CS before the arrival of bubbles</p>
<p>7.5b (see Video 90)</p> 	<p>Beat 9 demonstrates bubble arrival in CS before right side</p>


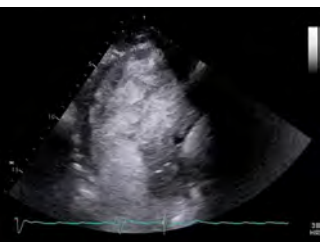

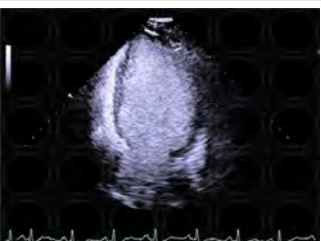
(Continued)

Table 7 (Continued)

2D TTE image	Information
7.5c (see Video 90) 	Beat 7 demonstrates bubbles in CS and right ventricle (arrow)

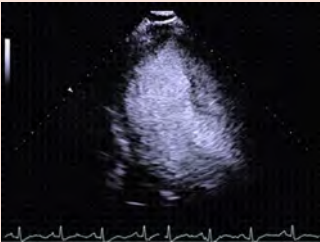


For Videos 87 to 90, see www.onlinejase.com.

Table 8 UEA imaging

		Image description
8.1 (see Video 91)		Apical window A4C view
8.2 (see Video 92)		Apical window Apical long-axis view Swirling artifact
8.3 (see Video 93)		Apical window A4C view LV opacification
8.4 (see Video 94)		Apical window A2C views LV opacification

(Continued)

Table 8 (Continued)

		Image description
8.5 (see Video 95)		Apical window Apical long-axis view LV opacification
8.6 (see Video 96)		Parasternal window PLAX view
8.7 (see Video 97)		Parasternal window PSAX view

For Videos 91 to 97, see www.onlinejase.com.

Table 9 Strain imaging

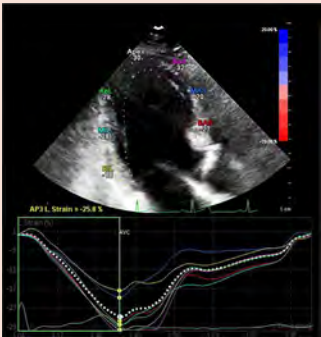
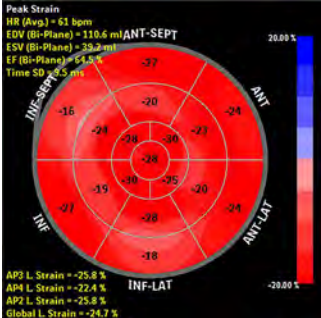
Strain 2D TTE image	2D TTE image name and measurements
	Apical window 3C
	Bull's-eye display of longitudinal strain calculations from each apical view and calculation of the global strain value

Table 10 Full-protocol images to acquire

Window	View/measurements	Clip/still frame
PLAX	LV increased depth, grayscale	Clip
PLAX	LV optimized sector depth, grayscale	Clip
PLAX	Linear measurement RVIDd	Still frame
PLAX	Linear measurement IVS diastole	Still frame
PLAX	Linear measurement LVIDd	Still frame
PLAX	Linear measurement LVPW diastole	Still frame
PLAX	Linear measurement LVIDs	Still frame
PLAX	Linear measurement LA systole	Still frame
PLAX	M-mode AV	Still frame
PLAX	M-mode AV LA dimension measurement	Still frame
PLAX	M-mode MV	Still frame
PLAX	M-mode left ventricle	Still frame
PLAX	Zoomed LVOT/AV, grayscale	Clip
PLAX	Zoomed LVOT/AV, color	Clip
PLAX	Zoomed MV, grayscale	Clip
PLAX	Zoomed MV, color	Clip
PLAX	Linear measurement zoomed LVOT diameter	Still frame
PLAX	Linear measurement zoomed Ao annular diameter	Still frame
PLAX	Zoomed STJ/SoVAo /AscAo, grayscale	Clip
PLAX	Zoomed STJ/SoVAo/AscAo, color	Clip
PLAX	Linear measurement STJAo diameter	Still frame
PLAX	Linear measurement SoVAo diameter	Still frame
PLAX	Focused Asc Ao, grayscale	Clip
PLAX	Linear measurement Asc Ao diameter	Still frame
PLAX	RVOT, grayscale	Clip
PLAX	RVOT, color	Clip
PLAX	RVOT, PW Doppler measure peak velocity and VTI	Still frame*
PLAX	PA CW Doppler measure peak velocity, VTI (PR if present)	Still frame*
PLAX	Linear measurement proximal RVOT diastole	Still frame
PLAX	RV inflow, grayscale	Clip
PLAX	RV inflow, color	Clip
PLAX	RV inflow if TR present, measure CW Doppler peak velocity	Still frame
PSAX	Great vessels (superior to AV, focused on PV, PA, and branches), grayscale	Clip
PSAX	RVOT, linear measurement RVOT, proximal and distal portions	Still frame
PSAX	Main PA, linear measurement	Still frame
PSAX	Large-sector view right atrium, TV, RV inflow, RVOT, AV, grayscale at AV level	Clip
PSAX	Narrow-sector view TV, right atrium, RV inflow, grayscale	Clip
PSAX	Narrow-sector view right atrium, TV, RV inflow, color	Clip
PSAX	Narrow-sector view right atrium, TV, if TR present measure CW Doppler peak velocity	Still Frame
PSAX	AV zoomed view showing valve leaflets	Clip
PSAX	AV zoomed view, color	Clip
PSAX	Narrow sector view RVOT, PV, PA, grayscale	Clip
PSAX	Narrow sector view RVOT, PV, PA, color	Clip
PSAX	RVOT, PW Doppler measure peak velocity and VTI	Still frame*
PSAX	PA CW Doppler measure peak velocity, VTI (PR if present)	Still frame*
PSAX	MV leaflet level, grayscale	Clip
PSAX	MV leaflet level, color	Clip
PSAX	LV just inferior to MV leaflet tips, grayscale	Clip
PSAX	LV mid papillary muscle level, grayscale	Clip
PSAX	LV apex level, grayscale	Clip

(Continued)

Table 10 (Continued)

Window	View/measurements	Clip/still frame
PSAX	Sweep from MV through papillary muscles to LV apex, color	Clip
Apical	A4C, grayscale	Clip
Apical	A4C, ventricular focus (adjusted sector width and depth), grayscale	Clip
Apical	A2C, grayscale	Clip
Apical	A2C ventricular focus (adjusted sector width and depth), grayscale	Clip
Apical	Apical long-axis, grayscale	Clip
Apical	Apical long-axis ventricular focus (adjusted sector width and depth), grayscale	Clip
Apical	Apical long-axis AV, color	Clip
Apical	Apical long axis, if AR present then CW Doppler through AV (measure deceleration slope)	Still frame
Apical	Apical long-axis MV, color	Clip
Apical	Apical long-axis MV, if MR present then CW Doppler through MV (measure peak velocity and VTI)	Still frame*
Apical	A2C MV, color	Clip
Apical	A2C MV, if MR present then CW Doppler through MV (measure peak velocity and VTI)	Still frame*
Apical	A4C MV, color	Clip
Apical	MV inflow, PW Doppler (measure E velocity, A velocity, E deceleration time, optional A velocity duration)	Still frame
Apical	MV inflow, if MS present, CW Doppler (measure E velocity, A velocity, E deceleration slope, VTI and mean gradient)	Still frame
Apical	A4C MV, if MR present then CW Doppler through MV (measure peak velocity and VTI)	Still frame*
Apical	DTI, MV lateral annulus, medial annulus (measure e', a', s')	Still frame
Apical	A4C Pulvns, grayscale	Clip
Apical	A4C Pulvns, color	Clip
Apical	Pulvn inflow, PW Doppler to show S, D, and A velocity waveforms)	Still frame
Apical	A4C LA volume (trace left atrium at end-systole, measure long-axis length)	Still frame
Apical	A2C LA volume (trace left atrium at end-systole, measure long-axis length)	Still frame
Apical	A4C ventricular focus, biplane summation of disks measure LV volume at end-diastole	Still frame
Apical	A4C ventricular focus, biplane summation of disks measure LV volume at end-systole	Still frame
Apical	A2C ventricular focus, biplane summation of disks measure LV volume at end-diastole	Still frame
Apical	A2C ventricular focus, biplane summation of disks measure LV volume at end-systole	Still frame
Apical	5C, grayscale	Clip
Apical	5C AV and LVOT, color	Clip
Apical	5C PW Doppler LVOT (measure peak velocity and VTI)	Still frame
Apical	5C CW Doppler AV (measure peak velocity and VTI)	Still frame
Apical	PW Doppler mapping from LV apex to LVOT to AV if necessary	Clip
Apical	CS, grayscale	Clip
Apical	RV-focused, grayscale	Clip
Apical	TV color inflow	Clip
Apical	TV inflow (optional measure E velocity, A velocity)	Still frame
Apical	TR if present (measure peak velocity)	Still frame
Apical	DTI TV lateral annulus s', e', a'	Still frame
Apical	RV-focused view, M-mode-TAPSE	Still frame
Apical	RV-focused view measure length, maximum basal transverse diameter, midcavity diameter at end-diastole	Still frame
Apical	RV-focused view measure area (tracing RV end-diastole)	Still frame
Apical	RV-focused view measure area (tracing RV end-systole)	Still frame
Apical	A4C view, RA volume (trace RA end-systole, measure length)	Still frame
Apical, optional	LV longitudinal strain	Clips
Apical, optional	3D LV function	Clips
SC	4C, grayscale	Clip
SC	4C, color	Clip

(Continued)

Table 10 (Continued)

Window	View/measurements	Clip/still frame
SC	IVC demonstrating variation with respiration	Clip
SC	IVC diameter measurement	Still frame
SC	Hvns, grayscale	Clip
SC	Hvns, color	Clip
SC	Hvns, PW Doppler to show S, D, and A velocity waveforms	Still frame
SSN	Aortic arch, grayscale	Clip
SSN	Aortic arch narrow-sector view color Doppler Asc Ao	Clip
SSN	Aortic arch PW Doppler Asc Ao peak velocity	Still frame
SSN	Aortic arch narrow-sector view transverse arch and Desc Ao, color	Clip
SSN	Aortic arch PW Doppler Desc Ao peak velocity (CW Doppler may also be used as necessary)	Still frame

LVIDs, LV internal dimension systole; *LVPW*, LV posterior wall; *MR*, mitral regurgitation; *MS*, mitral stenosis; *RVIDd*, RV internal dimension diastole; *STJ*, sinotubular junction; *TR*, tricuspid regurgitation.

*In these situations, the best of the multiple acquisition possibilities is sufficient.

Table 11 Limited echocardiographic examination protocols

Window	Limited Examination for Pericardial Effusion: View/Measurements	Clip/Still frame
PLAX	LV increased depth, grayscale	Clip
PLAX	LV optimized, grayscale	Clip
PLAX	M-mode MV	Still frame
PLAX	M-mode LV regular sweep speed (and slow sweep speed over multiple respiratory cycles if indicated)	Still frame and clip
PSAX	Large-sector view right atrium, TV, RV inflow, RVOT outflow, AV (emphasis on free wall motion)	Clip
PSAX	RVOT, PV, artery, branches, color	Clip
PSAX	RVOT, PW Doppler measure peak velocity and VTI and slow sweep speed over multiple respiratory cycles if indicated	Still frame and clip
PSAX	MV leaflet level, grayscale	Clip
PSAX	Left ventricle just inferior to MV leaflet tips, grayscale	Clip
PSAX	Mid LV papillary muscle level, grayscale	Clip
PSAX	LV apex level, grayscale	Clip
Apical	A4C, grayscale (emphasis on showing residual effusion, RV and RA wall motion)	Clip
Apical	A2C, grayscale	Clip
Apical	Apical long-axis, grayscale (emphasis on showing residual effusion)	Clip
Apical	MV inflow, PW Doppler (measure peak E and A velocities, slow sweep multirespiratory cycle clip if indicated)	Still frame and clip
Apical	5C, grayscale	Clip
Apical	5C LVOT measure peak velocity and VTI (PW Doppler with slow sweep multirespiratory cycle clip if indicated)	Still frame and clip
Apical	5C AV measure peak velocity and VTI (CW Doppler)	Still frame
Apical	RV-focused, grayscale (emphasis on showing residual effusion and free wall motion)	Clip
Apical	TV inflow (optional measure E and A velocities with slow sweep multirespiratory cycle clip if indicated)	Still frame
SC	4C, grayscale (emphasis on RV and RA free wall motion)	Clip
SC	IVC demonstrating variation with respiration	Clip
SC	IVC diameter measurement	Still frame
Window	Limited Examination for LV Function: View/Measurements	Clip/still frame
PLAX	LV increased depth, grayscale	Clip
PLAX	LV optimized, grayscale	Clip
PLAX	Linear measurement RVID diastole	Still frame
PLAX	Linear measurement IVS diastole	Still frame
PLAX	Linear measurement LVIDd	Still frame

(Continued)

Table 11 (Continued)

Window	Limited Examination for LV Function: View/Measurements	Clip/still frame
PLAX	Linear measurement LVPW diastole	Still frame
PLAX	Linear measurement LVIDs	Still frame
PLAX	M-mode MV	Still frame
PLAX	M-mode left ventricle	Still frame
PSAX	Left ventricle just inferior to MV leaflet tips, grayscale	Clip
PSAX	Mid LV papillary muscle level, grayscale	Clip
PSAX	LV apex level, grayscale	Clip
Apical	A4C, grayscale	Clip
Apical	A4C ventricular focus (adjusted sector width and depth), grayscale	Clip
Apical	A2C, grayscale	Clip
Apical	A2C ventricular focus (adjusted sector width and depth), grayscale	Clip
Apical	Apical long-axis, grayscale	Clip
Apical	Apical long-axis ventricular focus (adjusted sector width and depth), grayscale	Clip
Apical	A4C MV, color	Clip
Apical	MV inflow, PW Doppler (measure E velocity, A velocity, E deceleration time, optional A velocity duration)	Still frame
Apical	DTI MV lateral annulus, medial annulus (measure e' , a' , s')	Still frame
Apical	A4C LA volume (trace left atrium end-systole, measure length)	Still frame
Apical	A2C LA volume (trace left atrium end-systole, measure length)	Still frame
Apical	A4C ventricular focus, biplane volume summation of disks at end-diastole	Still frame
Apical	A4C ventricular focus, biplane volume summation of disks at end-systole	Still frame
Apical	A2C ventricle focus, biplane volume summation of disks at end-diastole	Still frame
Apical	A2C ventricular focus, biplane volume summation of disks at end-systole	Still frame
Apical	RV-focused, grayscale	Clip
Apical, optional	LV longitudinal strain from three apical views	Clips
Apical, optional	3D LV volume and function	Clips
SC	Four-chamber, grayscale	Clip
Window	Limited Examination for RV/Pulmonary Hypertension: View/Measurements	Clip/still frame
PLAX	LV increased depth, grayscale	Clip
PLAX	LV optimized, grayscale	Clip
PLAX	Linear measurement RVID diastole	Still frame
PLAX	M-mode MV	Still frame
PLAX	M-mode left ventricle	Still frame
PLAX	RVOT, grayscale	Clip
PLAX	RVOT, color	Clip
PLAX	RVOT, PW Doppler measure peak velocity and VTI	Still frame*
PLAX	PA CW Doppler measure peak velocity, VTI (PR if present)	Still frame*
PLAX	Linear measurement proximal RVOT	Still frame
PLAX	RV inflow, grayscale	Clip
PLAX	RV inflow, color	Clip
PLAX	RV inflow if TR present, measure CW Doppler peak velocity	Still frame
PSAX	Great vessels (superior to aorta, focused on pulmonary valve, artery and branches), grayscale	Clip
PSAX	Large-sector view right atrium, TV, RV inflow portion, RVOT, AV, grayscale at AV level	Clip
PSAX	Narrow-sector TV, right atrium, RV inflow, grayscale	Clip
PSAX	Narrow-sector view right atrium, TV, RV inflow portion RVOT, AV, color	Clip
PSAX	Narrow-sector view right atrium, TV, if TR present measure CW Doppler peak velocity	Still frame
PSAX	Narrow-sector view RVOT, pulmonary valve, PA, color	Clip
PSAX	RVOT, pulmonary valve, artery, branches, color	Clip
PSAX	RVOT, PW Doppler measure peak velocity and VTI	Still frame*

(Continued)

Table 11 (Continued)

Window	Limited Examination for RV/Pulmonary Hypertension: View/Measurements	Clip/still frame
PSAX	PA CW Doppler measure peak velocity, VTI (PR if present)	Still frame*
PSAX	LV just inferior to MV leaflet tips, grayscale	Clip
PSAX	Mid LV papillary muscle level, grayscale	Clip
PSAX	LV apex level, grayscale	Clip
Apical	A4C, grayscale	Clip
Apical	A2C, grayscale	Clip
Apical	Apical long-axis, grayscale	Clip
Apical	MV inflow, PW Doppler (measure E velocity, A velocity, E deceleration time)	Still frame
Apical	DTI MV lateral annulus, medial annulus (measure e', a', s')	Still frame
Apical	Right ventricle focused, grayscale	Clip
Apical	TV color inflow	Clip
Apical	TV inflow (optional measure E velocity, A velocity)	Still frame
Apical	TR if present (measure peak velocity)	Still frame
Apical	DTI TV lateral annulus (measure e', a', and s')	Still frame
Apical	RV-focused view, M-mode, TAPSE	Still frame
Apical	RV-focused view measure length, maximum basal transverse diameter, midcavity diameter	Still frame
Apical	RV-focused view trace area at end-diastole	Still frame
Apical	RV-focused view trace area at end-systole	Still frame
Apical	A4C view, RA volume summation of disks trace RA area at end-systole, measure length)	Still frame
SC	IVC demonstrating variation with respiration	Clip
SC	IVC diameter measurement	Still frame
SC	Hvns, color	Clip
SC	Hvns, PW Doppler to display S, D, and A velocity waveforms	Still frame

LVIDs, LV internal dimension systole; LVPW, LV posterior wall; TR, tricuspid regurgitation.

*Choose to display either PLAX or PSAX.

describe use of UEAs in detail. However, appropriate use of UEAs is considered an integral part of the routine transthoracic examination. An echocardiography laboratory should be provisioned with supplies and appropriate personnel to perform the procedure on demand during a routine study. Intravenous access is required. This section provides a brief description of the indications, instrumentation, administration techniques, and examples of UEA images. Operators are encouraged to become proficient in understanding when UEAs are indicated and be familiar with administration techniques and image optimization. All echocardiography laboratories should have established protocols for UEA administration.

1. Indications. Currently, the only US Food and Drug Administration–approved cardiac indication for the use of UEAs is to opacify the LV chamber and to improve delineation of the LV endocardial border. UEAs should be used in patients with suboptimal images for assessment of LV contractility, defined as the inability to detect endocardial motion in two or more contiguous segments in any of the three apical views.^{79,82}

Other off-label uses of UEAs that are widely used include assessment of cardiac masses and intracardiac thrombi when endocardial border detection is limited. Poor-quality spectral Doppler signals, particularly CW Doppler envelopes for tricuspid regurgitation and aortic stenosis, may be enhanced with UEAs. Operators are encouraged to assess the need for a UEA early during an examination to minimize the impact of ordering, preparing, and administering the enhancement agent on procedural time.

2. Instrumentation and Administration. Each ultrasound manufacturer has a different algorithm for UEA image processing and contrast settings. Common to all of them are techniques that cancel out or lessen the strength of the returning signal from the tissue and enhance the signal received from the microbubbles. This usually involves a tissue cancelation technique coupled with harmonic imaging at a low or very low mechanical index.^{79,82}

UEAs are administered intravenously using bolus or continuous infusion techniques. Although the bolus technique (straight bolus followed by a flush or diluted flush) is more commonly used, continuous infusion provides a more consistent concentration of enhancement agent replenishment, which can eliminate or lessen imaging artifacts.^{79,82}

The most common artifacts associated with UEA imaging are attenuation and swirling (Tables 8.1 and 8.2). Attenuation is caused by a high concentration of microbubbles in the near field and results in shadowing of distal structures. Swirling is an artifact that results when the rate of bubble destruction exceeds the rate of bubble replenishment. These common artifacts are easily resolved by varying the amount or rate of UEA administration.^{79,82}

3. Image Acquisition. UEA imaging is usually best performed from the apical window because the anterior position of the right ventricle can result in attenuation and shadowing when using parasternal views. Imaging is begun from the A4C view, followed by the A2C and the apical long-axis view. As the UEA concentration declines, the PLAX view and PSAX view may also be acquired. This sequence allows the assessment of all 17 LV segments. Imaging

from the parasternal window in the long- and short-axis views should also be performed after the apical views (Tables 8.3–8.7).^{79,82}

C. Strain Imaging

Imaging techniques that measure ventricular strain are increasingly being adopted in echocardiography laboratories. There are multiple types of deformation (strain) imaging available. Currently, the most useful clinical data come from application of longitudinal strain obtained by 2D speckle-tracking derived from apical imaging planes. The writing committee recommends that echocardiography laboratories that have ultrasound equipment capable of strain imaging develop laboratory protocols for acquiring appropriate apical images to calculate peak systolic strain of the segments of the left ventricle (note that ultrasound systems may display a 16-, a 17-, or an 18-segment model), display the results as a bull's-eye map, and calculate global longitudinal strain indices. Although a consensus document regarding standardization of deformation imaging has been published,⁸³ standardization among vendors continues to evolve, so precise normal ranges of values are not yet available. Serial strain imaging studies should therefore be performed on the same ultrasound system to reduce variability caused by different equipment and software. The timing definitions for end-diastole and end-systole should be standardized across the echocardiography laboratory. Minimum frame rates for high-quality image acquisition (generally >40 frames/sec) should be established. Recognition of appropriate segmental tracking quality is crucial for reproducible results. Technical performance details vary by manufacturer and should be fully reviewed with application specialists before adopting strain imaging into the echocardiography laboratory work flow (Table 9).

D. Three-Dimensional Evaluation of LV Size and Systolic Function

Three-dimensional imaging systems are becoming widely available. With transthoracic imaging, evaluation of LV size and systolic function is the most common 3D application currently in use.⁵⁷ Acquisition and data-processing steps for measuring an ejection fraction with a 3D volume set are dependent on the ultrasound system and software used to calculate the 3D volume, but some general image optimization techniques can be applied to all image acquisitions. To obtain a 3D volume of the left ventricle for calculation of ejection fraction, the heart should be imaged in the A4C view, focusing on the left ventricle. The 2D image should be optimized by adjusting the focus, gain, and compression. Prior publications⁵⁷ have suggested that both gain and compression should be set in midranges (i.e., 50) to allow adequate postprocessing of the 3D volume. After adjusting these settings, the TGC should be adjusted to further optimize the image. To maximize temporal and spatial resolution, the image field of view can be adjusted to allow the smallest volume that can capture the entire heart and increase the volume rate.⁵⁷ After the field of view for acquisition is set, good endocardial tissue definition should be confirmed. Once the imaging parameters are optimized, the patient should be asked to suspend respiration to help eliminate motion during acquisition. Multiple-beat acquisitions result in higher voxel rates and therefore better spatial resolution. Most systems will allow the operator to review the quality of the data set after acquisition. Semiautomated software is activated for tracing of the endocardial borders for volume calculation. The results of this calculation are then reviewed and recorded for display (Table 3.14).

X. THE INTEGRATED COMPLETE TRANSTHORACIC EXAMINATION

Table 10 provides a suggested sequence for all of the protocol images that define a comprehensive TTE examination. Each laboratory should make adjustments in the protocol to address needs of its particular patient populations and imaging equipment. Some parts of the protocol (marked with asterisks) may seem redundant. In these situations the best of the multiple acquisition possibilities is sufficient.

XI. THE LIMITED TRANSTHORACIC EXAMINATION

The Intersocietal Accreditation Commission defines a limited echocardiographic examination as follows: "A limited study is generally only performed when the patient has recently undergone a complete examination and there is no clinical reason to suspect any changes outside the specific area of interest. A limited study generally examines a single area of the heart or answers a single clinical question."⁴ Listed below are some common limited-examination sequences (Table 11).

A. Pericardial Effusion

A repeat study for evaluation of a pericardial effusion is commonly performed to serially follow the progress of treatment. The protocol emphasis is on views that define the presence and size of the effusion. If no effusion remains, views to evaluate for tamponade physiology are not necessary. If an effusion of significant size is present, the study should include imaging and Doppler data to make a full assessment of the hemodynamic significance of the effusion, as shown in the complete protocol in Table 11.

B. LV Function

LV function is often assessed to follow disease natural history and monitor patient response to treatment. The limited examination for LV function may be performed at variable time intervals after a full comprehensive echocardiographic examination when there is a focused clinical question regarding a change in LV function (Table 11).

C. Limited Right Ventricle and Pulmonary Hypertension

In individuals with pulmonary hypertension, echocardiography can be used to provide indirect measures of PA pressures and information regarding RV function, hypertrophy, and size.⁸⁴ Accurate assessment of pulmonary pressures and RV function is important to monitor the effect of treatment (Table 11).

The views described in this section are presented as a starting point for acquiring images for these limited-examination indications. The visualization of unexpected or new pathology may dictate addition of other images to these limited protocols.

ALTERNATIVE VIEWS

For certain clinical questions it may be desirable to image additional anatomic structures in multiple planes. The appendix to this document provides a table demonstrating alternative views and a brief description of when they may be used.

ACKNOWLEDGMENTS

We acknowledge and thank Melissa Bailey, BS, RDCS, RDMS, RVT, Julia M. Vaessen, BS, RDCS, RVT, and Shannon Johns, BS, RDCS, RVT, for assistance with acquiring images for this document and Rebecca J. Zart for her assistance with manuscript preparation. Original illustrations in this document were created using Medmovie (Medmovie, Lexington, KY).

This document was reviewed by members of the 2017–2018 ASE Guidelines and Standards Committee, ASE Board of Directors, and ASE Executive Committee. Reviewers included Bonita Anderson, MAPPLSC, DMU, AMS, FASE, ACS, Alicia Armour, BS, MA, RDCS, FASE, Federico M. Asch, MD, FASE, Azin Alizadehasl, MD, FASE, Joao L. Cavalcante, MD, FASE, Scott D. Choyce, RDCS, RVT, RDMS, FASE, Frederick C. Cobey, MD, FASE, Gregory J. Ensing, MD, FASE, Craig Fleishman, MD, FASE, Mark K. Friedberg, MD, FASE, Neal Gerstein, MD, FASE, Edward A. Gill, MD, FASE, Yvonne E. Gilliland, MD, FASE, Robi Goswami, MD, FASE, Lanqi Hua, RDCS (AE/PE/FE), FASE, Renuka Jain, MD, FASE, Pei-Ni Jone, MD, FASE, Jonathan R. Lindner, MD, FASE, Stephen H. Little, MD, FASE, Rick Meece, ACS, RDCS, RCS, RCIS, FASE, Maryellen H. Orsinelli, RN, RDCS, FASE, Andy Pellett, PhD, RCS, RDCS, FASE, Dermot Phelan, MD, PhD, FASE, Charlene M. Porcelli, RDCS, RDMS, FASE, David S. Rubenson, MD, FASE, Raymond, F. Stainback, MD, FASE, and David H. Wiener, MD, FASE.

NOTICE AND DISCLAIMER: This report is made available by ASE as a courtesy reference source for members. This report contains recommendations only and should not be used as the sole basis to make medical practice decisions or for disciplinary action against any employee. The statements and recommendations contained in this report are primarily based on the opinions of experts, rather than on scientifically-verified data. ASE makes no express or implied warranties regarding the completeness or accuracy of the information in this report, including the warranty of merchantability or fitness for a particular purpose. In no event shall ASE be liable to you, your patients, or any other third parties for any decision made or action taken by you or such other parties in reliance on this information. Nor does your use of this information constitute the offering of medical advice by ASE or create any physician-patient relationship between ASE and your patients or anyone else.

SUPPLEMENTARY DATA

Supplementary data related to this article can be found at <https://doi.org/10.1016/j.echo.2018.06.004>.

XII. REFERENCES

- Edler I, Hertz CH. The use of ultrasonic reflectoscope for the continuous recording of movements of heart walls 1954. *Clin Physiol Funct Imaging* 2004;24:118-36.
- Lang RM, Badano LP, Mor-Avi V, Afilalo J, Armstrong A, Ernande L, et al. Recommendations for cardiac chamber quantification by echocardiography in adults: an update from the American Society of Echocardiography and the European Association of Cardiovascular Imaging. *J Am Soc Echocardiogr* 2015;28:1-39.
- Nagueh SF, Smiseth OA, Appleton CP, Byrd BF, Dokainish H, Edvardsen T, et al. Recommendations for the evaluation of left ventricular diastolic function by echocardiography: an update from the American Society of Echocardiography and the European Association of Cardiovascular Imaging. *J Am Soc Echocardiogr* 2016;29:277-314.
- Intersocietal Accreditation Commission. IAC standards and guidelines for adult echocardiography accreditation. Available at: <http://www.intersocietal.org/echo/standards/IACAdultEchocardiographyStandards2017.pdf> 2017. Accessed June 25, 2018.
- Henry WL, DeMaria A, Gramiak R, King DL, Kisslo JA, Popp RL, et al. Report of the American Society of Echocardiography Committee on Nomenclature and Standards in Two-Dimensional Echocardiography. *Circulation* 1980;62:212-7.
- Picard MH, Adams D, Bierig SM, Dent JM, Douglas PS, Gillam LD, et al. American Society of Echocardiography recommendations for quality echocardiography laboratory operations. *J Am Soc Echocardiogr* 2011; 24:1-10.
- Wharton G, Steeds R, Allen J, Phillips H, Jones R, Kanagala P, Lloyd G, et al. A minimum dataset for a standard adult transthoracic echocardiogram: a guideline protocol from the British Society of Echocardiography. *Echo Res Pract* 2015;2:C9-24.
- Jeanrenaud X, Seiler C, Jost CA, Kaufmann B, Gruner C, Mueller H, et al. What is a standard transthoracic echocardiogram performed by a cardiologist? *Cardiovasc Med* 2015;18:146-51.
- Anderson B. The two-dimensional echocardiographic examination. In: Anderson B, editor. *Echocardiography: the normal examination and echocardiographic measurements*. 3rd ed. Sydney, Australia: Echotext; 2017.
- Otto CM. Principles of echocardiographic image acquisition and Doppler analysis. In: Otto CM, editor. *Textbook of clinical echocardiography*. 5th ed. Philadelphia: Elsevier Saunders; 2013. pp. 1-30.
- International Sonographer Training Task Force of the American Society of Echocardiography. International echo training module 1: basic instrumentation. Durham, NC: American Society of Echocardiography; 2015.
- International Sonographer Training Task Force of the American Society of Echocardiography. International echo training module 2: nomenclature transducer movements. Durham, NC: American Society of Echocardiography; 2015.
- American Institute of Ultrasound in Medicine. Transducer manipulation for echocardiography. *J Ultrasound Med* 2005;24:733-6.
- Otto CM. Normal anatomy and flow patterns on transthoracic echocardiography. In: Otto CM, editor. *Textbook of clinical echocardiography*. 5th ed. Philadelphia: Elsevier Saunders; 2013. pp. 31-64.
- Gibbs V, Cole D, Sassano A. *Ultrasound physics and technology e-book: how, why and when*. Edinburgh, United Kingdom: Churchill Livingstone Elsevier; 2011.
- Hill JC, Palma RA. Doppler tissue imaging for the assessment of left ventricular diastolic function: a systematic approach for the sonographer. *J Am Soc Echocardiogr* 2005;18:80-8.
- Zagzebski JA. Physics and instrumentation in Doppler and B-mode ultrasonography. In: Pellerito JS, Polak JF, editors. *Introduction to vascular ultrasonography*. 6th ed. Philadelphia: Elsevier Saunders; 2012. pp. 20-51.
- Zagzebski JA. Pulse-echo ultrasound instrumentation. In: Zagzebski JA, editor. *Essentials of ultrasound physics*. St. Louis, MO: Mosby; 1996. pp. 46-68.
- Huang ZH, Long WY, Xie GY, Kwan OL, DeMaria AN. Comparison of gray-scale and B-color ultrasound images in evaluating left ventricular systolic function in coronary artery disease. *Am Heart J* 1992;123:395-402.
- Comess KA, Beach KW, Hatsukami T, Strandness DE Jr., Daniel W. Pseudocolor displays in B-mode imaging applied to echocardiography and vascular imaging: an update. *J Am Soc Echocardiogr* 1992;5:13-32.
- Thomas JD, Rubin DN. Tissue harmonic imaging: why does it work? *J Am Soc Echocardiogr* 1998;11:803-8.
- Tranquart F, Grenier N, Eder V, Pourcelot L. Clinical use of ultrasound tissue harmonic imaging. *Ultrasound Med Biol* 1999;25:889-94.
- Anvari A, Forsberg F, Samir AE. A primer on the physical principles of tissue harmonic imaging. *Radiographics* 2015;35:1955-64.
- Rubin DN, Yazbek N, Garcia MJ, Stewart WJ, Thomas JD. Qualitative and quantitative effects of harmonic echocardiographic imaging on endocardial edge definition and side-lobe artifacts. *J Am Soc Echocardiogr* 2000;13:1012-8.

25. Senior R, Soman P, Khattar RS, Lahiri A. Improved endocardial visualization with second harmonic imaging compared with fundamental two-dimensional echocardiographic imaging. *Am Heart J* 1999;138:163-8.
26. Masencal N, Bordachar P, Chatellier G, Redheuil A, Diebold B, Abergel E. Comparison of accuracy of left ventricular echocardiographic measurements by fundamental imaging versus second harmonic imaging. *Am J Cardiol* 2003;91:1037-9.
27. Spencer KT, Bednarz J, Rafter PG, Korcarz C, Lang RM. Use of harmonic imaging without echocardiographic contrast to improve two-dimensional image quality. *Am J Cardiol* 1998;82:794-9.
28. Hawkins K, Henry JS, Krasuski RA. Tissue harmonic imaging in echocardiography: better valve imaging, but at what cost? *Echocardiography* 2008;25:119-23.
29. Barr RG, Grajo JR. Dynamic automatic ultrasound optimization: time savings, keystroke savings, and image quality. *Ultrasound Q* 2009;25:63-5.
30. Quiñones MA, Otto CM, Stoddard M, Waggoner A, Zoghbi WA, Doppler Quantification Task Force of the Nomenclature and Standards Committee of the American Society of Echocardiography. Recommendations for quantification of Doppler echocardiography: a report from the Doppler quantification task force of the nomenclature and standards committee of the American Society of Echocardiography. *J Am Soc Echocardiogr* 2002;15:167-84.
31. Wann S, Passen E. Echocardiography in pericardial disease. *J Am Soc Echocardiogr* 2008;21:7-13.
32. Pérez-Casares A, Cesar S, Brunet-Garcia L, Sanchez-de-Toledo J. Echocardiographic evaluation of pericardial effusion and cardiac tamponade. *Front Pediatr* 2017;5:1-10.
33. Otto CM. Pericardial disease. In: Otto CM, editor. *Textbook of clinical echocardiography*. 5th ed. Philadelphia: Elsevier Saunders; 2013. pp. 254-70.
34. Pellerito JS, Polak JF. Basic concepts of Doppler frequency spectrum analysis and ultrasound blood flow imaging. In: Pellerito JS, Polak JF, editors. *Introduction to vascular ultrasonography*. 6th ed. Philadelphia: Elsevier Saunders; 2012. pp. 52-73.
35. Baumgartner H, Hung J, Bermejo J, Chambers JB, Edvardsen T, Goldstein S, et al. Recommendations on the echocardiographic assessment of aortic valve stenosis: a focused update from the European Association of Cardiovascular Imaging and the American Society of Echocardiography. *J Am Soc Echocardiogr* 2017;30:372-92.
36. Stewart WJ, Galvin KA, Gillam LD, Guyer DE, Weyman AE. Comparison of high pulse repetition frequency and continuous wave Doppler echocardiography in the assessment of high flow velocity in patients with valvular stenosis and regurgitation. *J Am Coll Cardiol* 1985;6:565-71.
37. Baumgartner H, Hung J, Bermejo J, Chambers JB, Evangelista A, Griffin BP, et al. Echocardiographic assessment of valve stenosis: EAE/ASE recommendations for clinical practice. *J Am Soc Echocardiogr* 2009;22:1-23.
38. Nagueh SF, Middleton KJ, Kopelen HA, Zoghbi WA, Quiñones MA. Doppler tissue imaging: a noninvasive technique for evaluation of left ventricular relaxation and estimation of filling pressures. *J Am Coll Cardiol* 1997;30:1527-33.
39. Nagueh SF, Sun H, Kopelen HA, Middleton KJ, Khoury DS. Hemodynamic determinants of the mitral annulus diastolic velocities by tissue Doppler. *J Am Coll Cardiol* 2001;37:278-85.
40. Ho CY, Solomon SD. A clinician's guide to tissue Doppler imaging. *Circulation* 2006;113:e396-8.
41. Nikitin NP, Witte KK, Thackray SD, de Silva R, Clark AL, Cleland JG. Longitudinal ventricular function: Normal values of atrioventricular annular and myocardial velocities measured with quantitative two-dimensional color Doppler tissue imaging. *J Am Soc Echocardiogr* 2003;16:906-21.
42. Miyatake K, Okamoto M, Kinoshita N, Izumi S, Owa M, Takao S, et al. Clinical applications of a new type of real-time two-dimensional Doppler flow imaging system. *Am J Cardiol* 1984;54:857-68.
43. Zoghbi WA, Adams D, Bonow RO, Enriquez-Sarano M, Foster E, Grayburn PA, et al. Recommendations for noninvasive evaluation of native valvular regurgitation: a report from the American Society of Echocardiography developed in collaboration with the Society for Cardiovascular Magnetic Resonance. *J Am Soc Echocardiogr* 2017;30:303-71.
44. Thomas JD, Liu CM, Flachskampf FA, O'Shea JP, Davidoff R, Weyman AE. Quantification of jet flow by momentum analysis. An in vitro color Doppler flow study. *Circulation* 1990;81:247-59.
45. Thomas JD. Doppler echocardiographic assessment of valvar regurgitation. *Heart* 2002;88:651-7.
46. Kronzon I, Aurigemma GP. M-mode echocardiography. In: Lang RM, Goldstein SA, Kronzon I, Khandheria BK, Mor-Avi V, editors. *ASE's comprehensive echocardiography*. 2nd ed. Philadelphia: Elsevier Saunders; 2016. pp. 30-8.
47. Brun P, Tribouilloy C, Duval AM, Iserin L, Meguira A, Pelle G, et al. Left ventricular flow propagation during early filling is related to wall relaxation: a color M-mode Doppler analysis. *J Am Coll Cardiol* 1992;20:420-32.
48. Garcia MJ, Smedira NG, Greenberg NL, Main M, Firstenberg MS, Odabashian J, et al. Color M-mode Doppler flow propagation velocity is a preload insensitive index of left ventricular relaxation: animal and human validation. *J Am Coll Cardiol* 2000;35:201-8.
49. Takatsui H, Mikami T, Urasawa K, Teranishi J-I, Onozuka H, Takagi C, et al. A new approach for evaluation of left ventricular diastolic function: spatial and temporal analysis of left ventricular filling flow propagation by color M-mode Doppler echocardiography. *J Am Coll Cardiol* 1996;27:365-71.
50. Careri S, Micari A, Trono A, Giordano G, Cerrito M, Zito C, et al. Anatomical M-mode: an old-new technique. *Echocardiography* 2003;20:357-61.
51. Donal E, Coisne D, Pham B, Ragot S, Herpin D, Thomas JD. Anatomic M-Mode, a pertinent tool for the daily practice of transthoracic echocardiography. *J Am Soc Echocardiogr* 2004;17:962-7.
52. Otto CM. The echo exam: quick reference guide basic principles. In: Otto CM, editor. *Textbook of clinical echocardiography*. 5th ed. Philadelphia: Elsevier; 2013. pp. 500-3.
53. Drew BJ, Califf RM, Funk M, Kaufman ES, Krucoff MW, Laks MM, et al. Practice standards for electrocardiographic monitoring in hospital settings: an American Heart Association scientific statement from the Councils on Cardiovascular Nursing, Clinical Cardiology, and Cardiovascular Disease in the Young: endorsed by the International Society of Computerized Electrocardiology and the American Association of Critical-Care Nurses. *Circulation* 2004;110:2721-46.
54. Snider RA, Serwer GA, Ritter SB. The normal echocardiographic examination. In: Snider RA, Serwer GA, Ritter SB, editors. *Echocardiography in pediatric heart disease*. 2nd ed. St. Louis, MO: Mosby; 1997. pp. 22-75.
55. Lai WW, Ko HH. The normal pediatric echocardiogram. In: Lai WW, Mertens LL, Cohen MS, Geva T, editors. *Echocardiography in pediatric and congenital heart disease from fetus to adult*. Hoboken, NJ: Wiley-Blackwell; 2009. pp. 34-52.
56. Brown LM, Duffy CE, Mitchell C, Young L. A practical guide to pediatric coronary artery imaging with echocardiography. *J Am Soc Echocardiogr* 2015;28:379-91.
57. Lang RM, Badano LP, Tsang W, Adams DH, Agricola E, Buck T, et al. EAE/ASE recommendations for image acquisition and display using three-dimensional echocardiography. *J Am Soc Echocardiogr* 2012;25:3-46.
58. Rudski LG, Lai WW, Afilalo J, Hua L, Handschumacher MD, Chandrasekaran K, et al. Guidelines for the echocardiographic assessment of the right heart in adults: a report from the American Society of Echocardiography endorsed by the European Association of Echocardiography, a registered branch of the European Society of Cardiology, and the Canadian Society of Echocardiography. *J Am Soc Echocardiogr* 2010;23:685-713.
59. Horton KD, Meece RW, Hill JC. Assessment of the right ventricle by echocardiography: a primer for cardiac sonographers. *J Am Soc Echocardiogr* 2009;22:776-92.
60. Aloia E, Cameli M, D'Ascenzi F, Sciacaluga C, Mondillo S. TAPSE: an old but useful tool in different diseases. *Int J Cardiol* 2016;225:177-83.
61. Kaul S, Tei C, Hopkins JM, Shah PM. Assessment of right ventricular function using two-dimensional echocardiography. *Am Heart J* 1984;107:526-31.

62. Keren A, Billingham ME, Popp RL. Echocardiographic recognition of para-septal structures. *J Am Coll Cardiol* 1985;6:913-9.
63. Canepa M, Malti O, David M, AlGhatrif M, Strait JB, Ameri P, et al. Prevalence, clinical correlates, and functional impact of subaortic ventricular septal bulge (from the Baltimore Longitudinal Study of Aging). *Am J Cardiol* 2014;114:796-802.
64. Canepa M, Pozios I, Vianello PF, Ameri P, Brunelli C, Ferrucci L, et al. Distinguishing ventricular septal bulge versus hypertrophic cardiomyopathy in the elderly. *Heart* 2016;102:1087-94.
65. Muraru D, Maffessanti F, Kocabay G, Peluso D, Dal Bianco L, Piasentini E, et al. Ascending aorta diameters measured by echocardiography using both leading edge-to-leading edge and inner edge-to-inner edge conventions in healthy volunteers. *Eur Heart J Cardiovasc Imaging* 2014;15:415-22.
66. Tamborini G, Piazzese C, Lang RM, Muratori M, Chiorino E, Mapelli M, et al. Feasibility and accuracy of automated software for transthoracic three-dimensional left ventricular volume and function analysis: comparisons with two-dimensional echocardiography, three-dimensional transthoracic manual method, and cardiac magnetic resonance imaging. *J Am Soc Echocardiogr* 2017;30:1049-58.
67. Abhayaratna WP, Seward JB, Appleton CP, Douglas PS, Oh JK, Tajik AJ, et al. Left atrial size: physiologic determinants and clinical applications. *J Am Coll Cardiol* 2006;47:2357-63.
68. Jenkins C, Bricknell K, Marwick TH. Use of real-time three-dimensional echocardiography to measure left atrial volume: comparison with other echocardiographic techniques. *J Am Soc Echocardiogr* 2005;18:991-7.
69. Meltzer RS, McGhie J, Roelandt J. Inferior vena cava echocardiography. *J Clin Ultrasound* 1982;10:47-51.
70. Pasquero P, Albani S, Sitia E, Taulaigo AV, Borio L, Berchiolla P, et al. Inferior vena cava diameters and collapsibility index reveal early volume depletion in a blood donor model. *Crit Ultrasound J* 2015;7:17. <https://doi.org/10.1186/s13089-015-0034-4>.
71. Stainback RF, Estep JD, Agler DA, Birks EJ, Bremer M, Hung J, et al. Echocardiography in the management of patients with left ventricular assist devices: recommendations from the American Society of Echocardiography. *J Am Soc Echocardiogr* 2015;28:853-909.
72. Otto CM. Valvular stenosis. In: Otto CM, editor. *Textbook of clinical echocardiography*. 5th ed. Philadelphia: Elsevier Saunders; 2013. pp. 271-304.
73. Jassal DS, Thakrar A, Schaffer SA, Fang T, Kirkpatrick I, Tam JW, et al. Percutaneous balloon valvuloplasty for pulmonic stenosis: the role of multimodality imaging. *Echocardiography* 2008;25:231-5.
74. Parasuraman S, Walker S, Loudon BL, Gollop ND, Wilson AM, Lowery C, et al. Assessment of pulmonary artery pressure by echocardiography—a comprehensive review. *Int J Cardiol Heart Vasc* 2016;12:45-51.
75. Dumesnil JG, Yoganathan AP. Theoretical and practical differences between the Gorlin formula and the continuity equation for calculating aortic and mitral valve areas. *Am J Cardiol* 1991;67:1268-72.
76. Hurrell DG, Nishimura RA, Ilstrup DM, Appleton CP. Utility of preload alteration in assessment of left ventricular filling pressure by Doppler echocardiography: a simultaneous catheterization and Doppler echocardiographic study. *J Am Coll Cardiol* 1997;30:459-67.
77. Klein AL, Tajik AJ. Doppler assessment of pulmonary venous flow in healthy subjects and in patients with heart disease. *J Am Soc Echocardiogr* 1991;4:379-92.
78. Silvestry FE, Cohen MS, Arnsby LB, Burkule NJ, Fleishman CE, Hijazi ZM, et al. Guidelines for the echocardiographic assessment of atrial septal defect and patent foramen Ovale: from the American Society of Echocardiography and Society for Cardiac Angiography and Interventions. *J Am Soc Echocardiogr* 2015;28:910-58.
79. Porter TR, Abdelmoneim S, Belcik JT, McCulloch ML, Mulvagh SL, Olson JJ, et al. Guidelines for the cardiac sonographer in the performance of contrast echocardiography: a focused update from the American Society of Echocardiography. *J Am Soc Echocardiogr* 2014;27:797-810.
80. Romero JR, Frey JL, Schwamm LH, Demaerschalk BM, Chaliki HP, Parikh G, et al. Cerebral ischemic events associated with 'bubble study' for identification of right to left shunts. *Stroke* 2009;40:2343-8.
81. Senior R, Becher H, Monaghan M, Agati L, Zamorano J, Vanoverschelde JL, et al. Contrast echocardiography: evidence-based recommendations by European Association of Echocardiography. *Eur J Echocardiogr* 2009;10:194-212.
82. Porter TR, Mulvagh SL, Abdelmoneim SS, Becher H, Belcik JT, Bierig M, et al. Clinical applications of ultrasonic enhancing agents in echocardiography: 2018 American Society of Echocardiography guidelines update. *J Am Soc Echocardiogr* 2018;31:241-74.
83. Voigt JU, Pedrizzetti G, Lysyansky P, Marwick TH, Houle H, Bauman R, et al. Definitions for a common standard for 2D speckle tracking echocardiography: consensus document of EACVI/ASE/Industry Task Force to standardize deformation imaging. *Eur Heart J Cardiovasc Imaging* 2015;16:1-11.
84. Barnett C, Ben-Yehuda O. Cardiac catheterization in the patient with pulmonary hypertension. In: Yuan JX-J, Garcia JGN, Hales CA, Rich S, Archer SL, West JB, editors. *Textbook of pulmonary vascular disease*. New York: Springer; 2011. pp. 1387-402.

XIII. APPENDIX: ADDITIONAL ALTERNATIVE VIEWS

This appendix is compiled with additional views that may be of value when an echocardiographic examination is needed to answer a specific question.

A. PSAX Coronary Artery View

The PSAX view imaged just superior to the location of the AV can be used to demonstrate the origin of the coronary arteries (Table 12.1). The right coronary artery typically is in the 11 o'clock position, and the origin of the left coronary artery is usually in the 5 o'clock position. To image the coronary artery origin, begin in the zoomed PSAX view just superior to the level of the AV and optimize the image. This image should demonstrate all borders of the aorta and allow enough room in all directions to be able to demonstrate the coronary artery origins and the initial course of each vessel. In some individuals, both coronary arteries may be seen in the same view. More commonly, each coronary artery is present in a slightly different plane. Sweep superior to inferior, slightly rotating counterclockwise to bring in the origin of the right coronary artery and clockwise to bring in the origin of the left coronary artery.¹

B. RV A2C View

Another view that can be used evaluate the right ventricle is the two-chamber RV view. To obtain this view, start from the focused RV four-chamber view and rotate 60° counterclockwise (as one does for the two-chamber LV view). The SVC, right atrium, and right ventricle (inferior RV free wall) will be visible. The AV will be seen in part as well. This view can be helpful to evaluate for endocarditis and thrombi on pacer leads and catheters coming from the SVC. This view may also allow a more parallel vector for color and spectral Doppler assessment of TV regurgitation (Table 12.2).

C. SC SVC (Bicaval) View

In some individuals, the SVC can also be seen entering the right atrium from a variation on the SC long-axis IVC imaging plane. To image the SVC, optimize the image of the long axis of the IVC, increase the depth, and angle the transducer toward the head, bringing the SVC into view. The SVC will be at the bottom of the sector at about 5 to 6 o'clock. The RA junction of the IVC and the SVC can be seen. This view is helpful to evaluate SVC flow, leads and catheters arising from the SVC, and atrial shunts, including those from the sinus venous (Table 12.3).

D. SC Abdominal Aorta

From the SC long-axis image of the IVC, angle and slide slightly leftward to image the aorta in long axis. The aorta is typically more vertical than the IVC. The vessel is oriented so that superior aspect is at the bottom of the sector and the inferior aspect is at the top. Color Doppler and pulsed Doppler show forward flow moving upward and to the left in the sector. The two-dimensional and Doppler views are helpful to image for aortic aneurysm, dissection, and atherosclerosis. This vessel does not respond to changes in respiration, which can help differentiate it from the IVC (Tables 12.4a and 12.4b).

E. Right Lateral Imaging of the IVC

In patients with poor sound transmission in the mid-SC window (i.e., abdominal bowel gas) or postoperative bandages, IVC imaging may

be accomplished by imaging through the liver in a right lateral decubitus imaging plane. This is often helpful with intensive care unit patients, who may be difficult to image. This image may be acquired in the supine position or by positioning the patient on his or her left side. Place the transducer on the patient's right side, just below the rib cage. Image through the liver to demonstrate the IVC and aorta in the same plane (Table 12.5).

F. SC Short-Axis IVC

The IVC can also be evaluated in the short axis. To acquire this image, rotate 90° from the IVC long-axis view, and the IVC will be demonstrated in cross-section on the right side of the body when normal cardiac and abdominal situs is present. This view is helpful to determine changes with respiration and also may be helpful for ensuring that the long-axis IVC image is in the center of the vessel, demonstrating its maximum diameter and thus maximum changes in diameter with respiration. A sweep of the ultrasound beam from this transverse view up to the heart can demonstrate pleural effusions (Table 12.6).

G. SC Focused Interatrial Septum

The interatrial septum can be magnified in the SC view to further evaluate for atrial septal aneurysm and/or echo dropout, which may indicate an atrial septal defect or patent foramen ovale. CDI can also be used in this view to interrogate the atrial septum for color crossing the septum, indicating that a septal defect is present. The color velocity scale is often reduced to adequately display color flow (Table 12.7).

H. SC Short-Axis RVOT View

This view can be used to evaluate the RVOT, PV, and main PA. This view provides an excellent Doppler angle to evaluate flow in these structures and is helpful for Doppler measures to evaluate for PV stenosis and PV regurgitation. This is an alternative for use when parasternal views are of limited quality (Table 12.8).

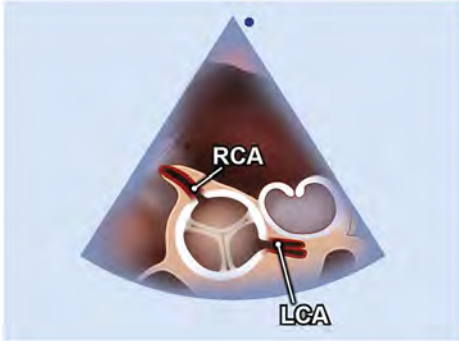
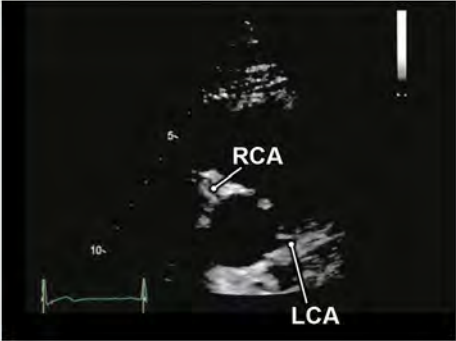
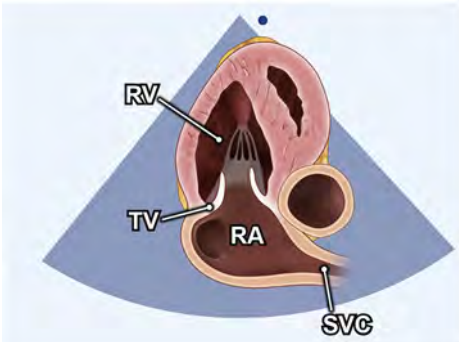
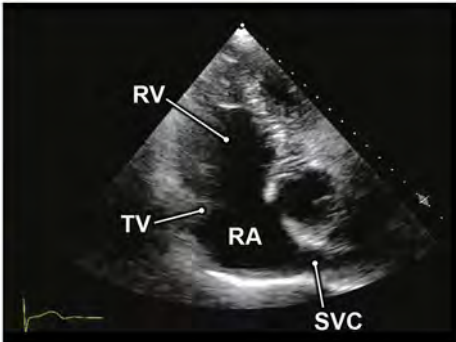
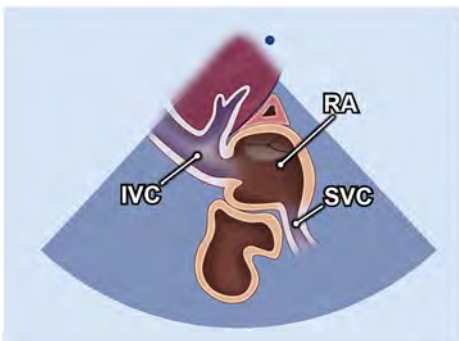
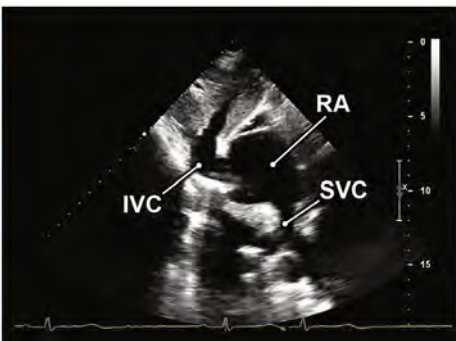
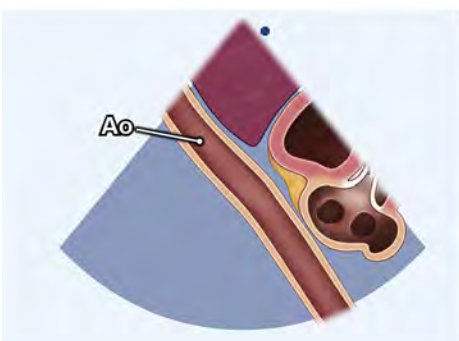

I. SC Short-Axis Sweep from the Level of the Great Arteries through the Apex of the Heart

In individuals with difficult parasternal and apical windows, the SC window can provide a window for completing LV function assessment. This sweep is a substitute for the PSAX sweep of the left ventricle and avoids the rib problem with the precordium. Start at the great vessel level and sweep toward the apex of the left ventricle. Anatomy, function, and septal defects can be evaluated with this view. Multiple clips may be obtained at all the same levels used in the PSAX views (Tables 12.9a and 12.9b).

J. Right Parasternal View of the Aorta

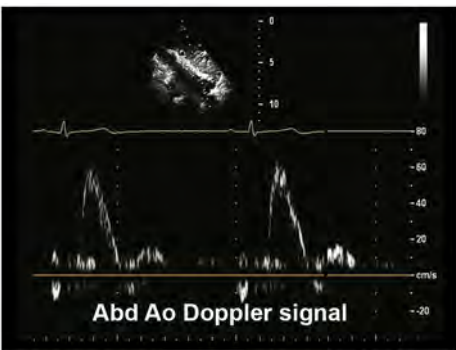
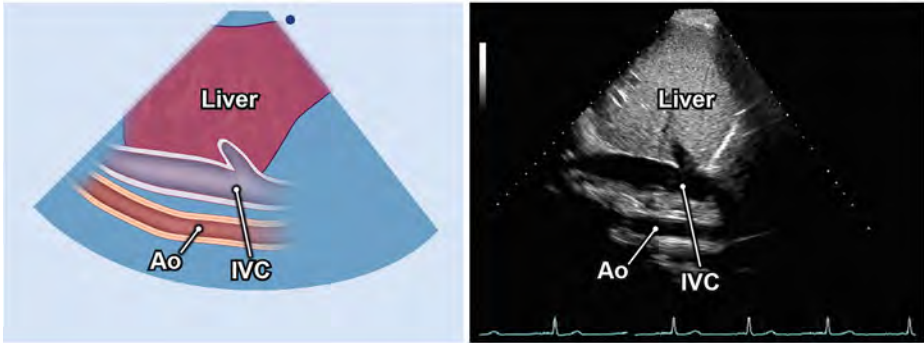
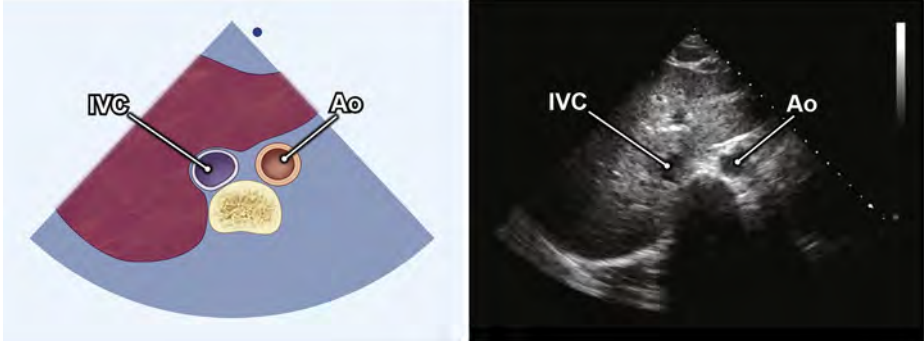
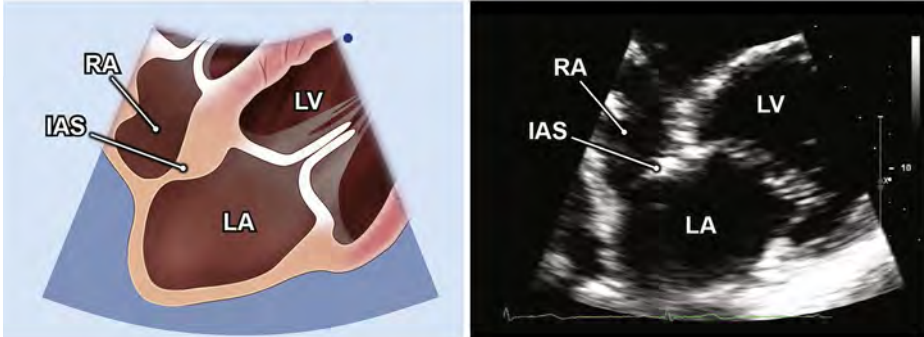
In cases in which aortic stenosis is present and the sonographer is having difficulty obtaining the aortic Doppler signal with the nonimaging CW transducer, an imaging transducer can be used to identify the Asc Ao. Place the patient in the right lateral decubitus position, and extend the right arm above the head. Place the transducer in the second or third intercostal space along the right border of the sternum. Align the index marker toward the patient's right shoulder. The Asc Ao is imaged in a long-axis plane as it leaves the heart. A Doppler image may be obtained from this view, and/or the sonographer may switch to the nonimaging CW transducer after locating the best window for obtaining a Doppler signal (Tables 12.10a–12.10c).

Table 12 Alternative views

Anatomic image	Echocardiographic image	When used
<p>12.1. PSAX coronary arteries (see Video 98)</p> 		<p>Parasternal window PSAX view Origin of coronary arteries Used when there is a need to locate the origins of the coronary arteries.</p>
<p>12.2. RV two-chamber (see Video 99)</p> 		<p>Apical window RV two-chamber view Used to evaluate the junction of the right atrium and SVC, additional regions of the right ventricle for RV function, the location of and suspected pathology on device leads and catheters, and structure and function of the TV.</p>
<p>12.3. Subcostal SVC (see Video 100)</p> 		<p>Subcostal window Alternate view of SVC Used to evaluate SVC inflow velocity, size, device leads, catheters, and potential obstructive pathology. The right atrium and IVC are also seen in this view.</p>
<p>12.4a. Subcostal long-axis abdominal aorta (see Video 101)</p> 		<p>Subcostal window Upper abdominal aorta Used to screen for abdominal aortic aneurysms, dissection, atherosclerotic plaques.</p>

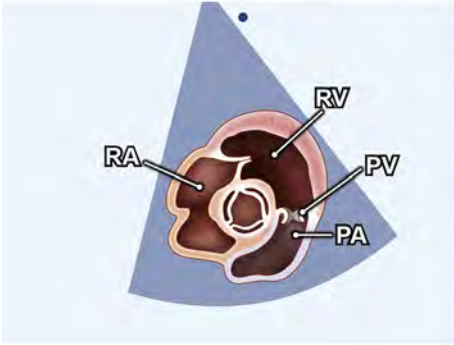
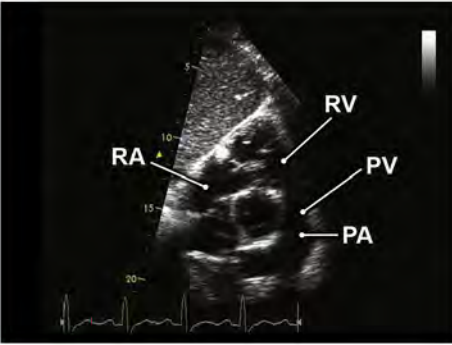
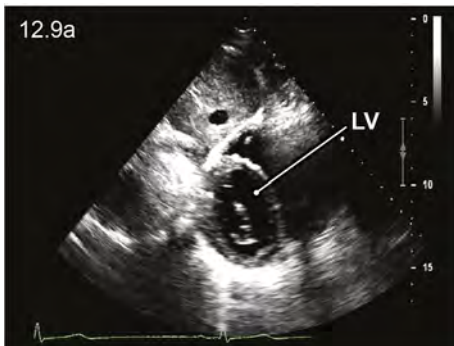

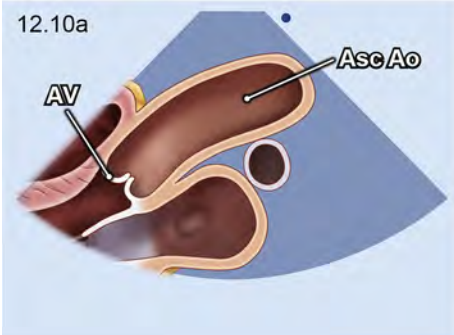
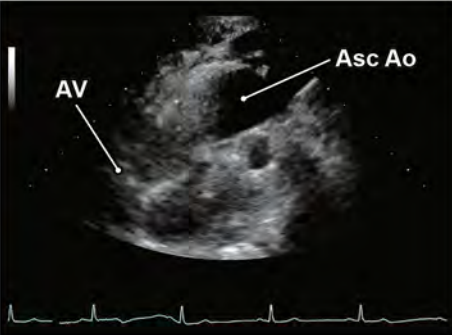
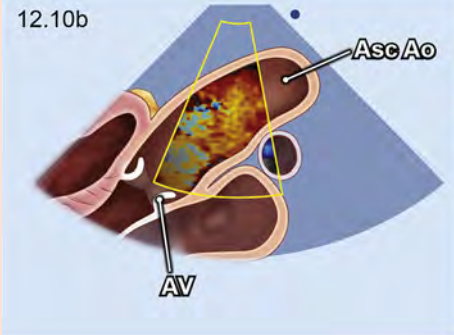
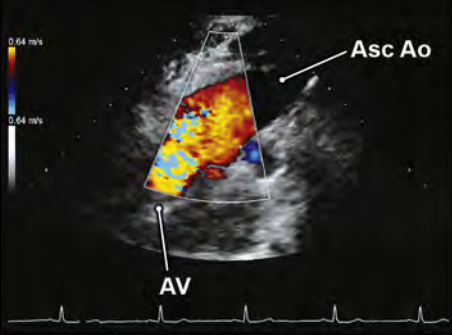
(Continued)

Table 12 (Continued)

Anatomic image	Echocardiographic image	When used
12.4b. Abdominal aorta Doppler		Subcostal window Upper abdominal aorta flow Used to evaluate systolic and diastolic flow patterns.
12.5. Right lateral IVC (see Video 102)		Subcostal window IVC view In patients with abdominal bowel gas, IVC imaging may be accomplished by imaging through the liver in a right lateral decubitus imaging plane.
12.6. Transverse IVC (see Video 103)		Subcostal window Transverse view of the IVC and descending aorta Used to confirm the actual maximal diameter of the IVC when there is concern that the long-axis imaging plane may not be demonstrating the center of the IVC.
12.7. Focused interatrial septum (see Video 104)		Subcostal window IAS Zoomed focused image of the IAS, used to evaluate for atrial septal defect or PFO.

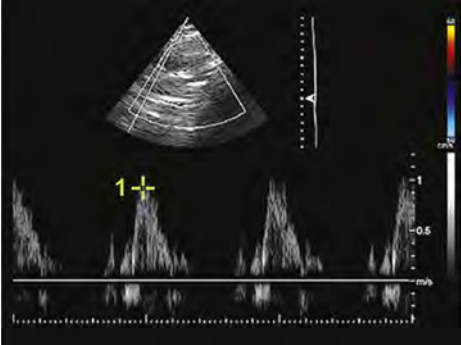
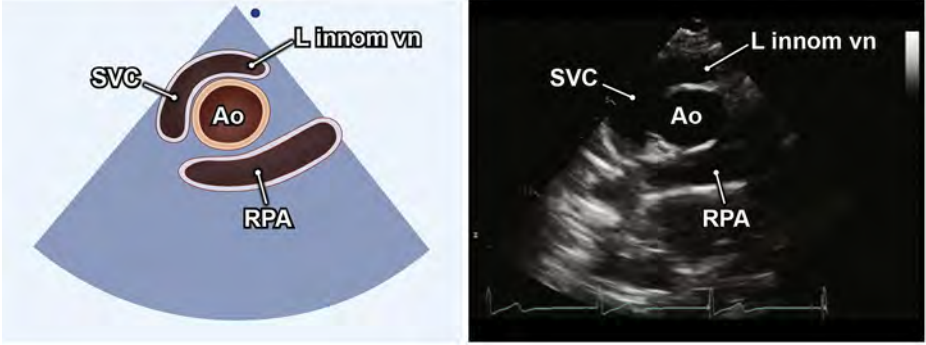
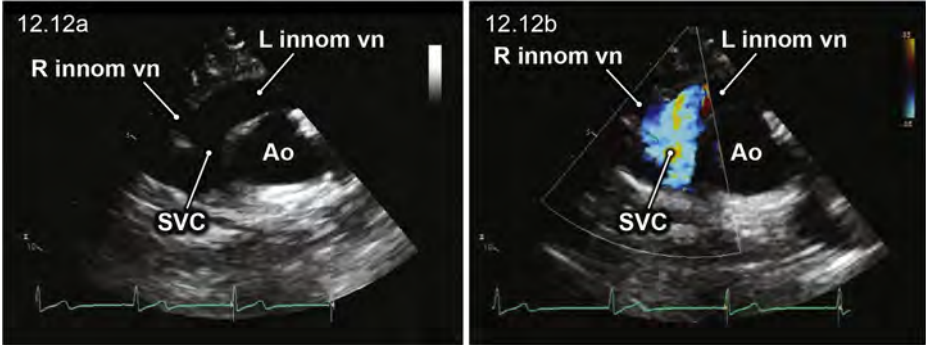
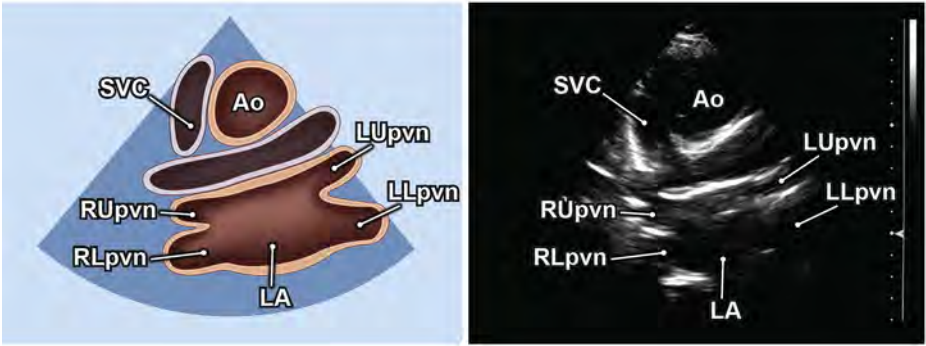
(Continued)

Table 12 (Continued)

Anatomic image	Echocardiographic image	When used
12.8. Subcostal short-axis RVOT (see Video 105)		
		Subcostal window RVOT, PV, MPA Used to evaluate structure and flow of the MPA, PV, and RVOT.
12.9. Subcostal short-axis sweep from the level of the great arteries through the apex of the heart (see Videos 106 and 107)		
12.9a 	12.9b 	Subcostal window Sweep for LV morphology and function In individuals with difficult parasternal and apical windows, the subcostal window is an alternative for completing LV function assessment.
12.10. High right parasternal view of aorta (see Videos 108 and 109)		
12.10a 		Right parasternal upper window Asc Ao This view is used to demonstrate flow in the Asc Ao. Often the aorta is imaged at a good Doppler angle from this view, and therefore this view may provide the highest Doppler velocities for assessment of aortic pathology.
12.10b 		Color Doppler of Asc Ao

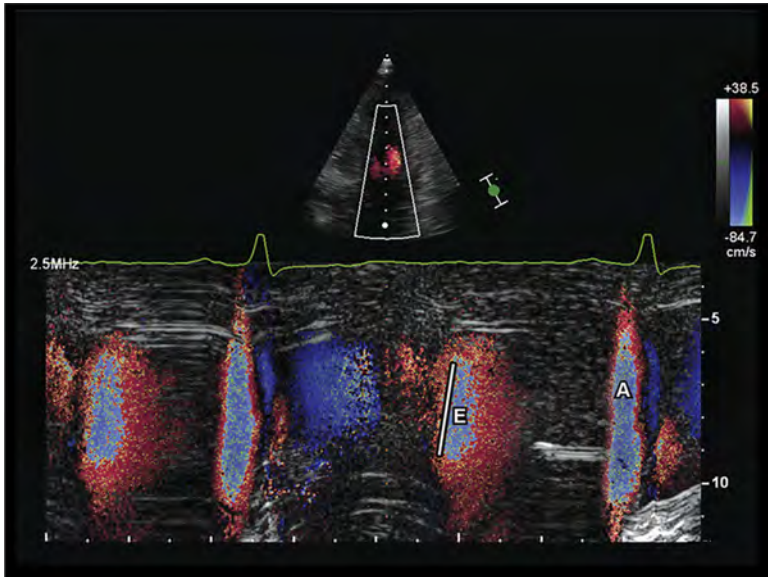
(Continued)

Table 12 (Continued)

Anatomic image	Echocardiographic image	When used
12.10c		1. Peak systolic AV velocity
12.11. SSN view left innominate vein, SVC, and right PA (see Video 110)		SSN window Short axis orientation Used to evaluate the left innominate vein, SVC, and PA.
12.12. SSN view innominate veins and SVC (see Videos 111 and 112)		SSN window SVC, R innom vn, L innom vn Used to evaluate the structure and flow of the R innom vn, L innom vn, and SVC.
12.13. SSN (see Video 113)		SSN window Crab view demonstrating right pulmonary artery, left atrium, and four Pulvns Used to evaluate Pulvn connections.

(Continued)

Table 12 (Continued)

Anatomic image	Echocardiographic image	When used
12.14. Color M-mode flow propagation	 <p>The image shows a color M-mode Doppler flow propagation study. At the top, a small inset shows the apical A4C view with a white box indicating the area of interest. Below, the main image displays the mitral inflow jet in color (red and blue) over time. A color M-mode box is drawn over the jet, and a white line labeled 'E' indicates the slope of the early diastolic flow propagation. A color scale on the right indicates velocities from +38.5 to -84.7 cm/s. The x-axis represents time, and the y-axis represents spatial distance. A 2.5 MHz frequency is noted on the left.</p>	<p>Apical window A4C view Color M mode This measure may be helpful in evaluation of diastolic dysfunction. The propagation velocity of the E wave is measured by measuring the slope (solid line).</p>

For Videos 98 to 113, see www.onlinejase.com.

K. SSN Innominate Veins

The standard longitudinal view may partially demonstrate a structure anterior to the aortic arch. This is usually the innominate vein. To fully demonstrate this vein, rotate the transducer into a transverse plane of the aorta (Table 12.11). Tilt the transducer inferior to demonstrate the left and right innominate veins draining into the SVC (Table 12.12a). Color flow imaging can be used to further demonstrate the venous anatomy and demonstrate patency of the veins (Table 12.12b).

A variation of this view, tilting the transducer toward the sternum and slightly rightward, shows the SVC entering the right atrium with the proximal Asc Ao to the left. The AV can be seen in the far field.

L. SSN Short-Axis LA and Pulvn View (“Crab View”)

From the SSN transverse position, lay the tail of the transducer almost parallel with the sternum. The left atrium with the four Pulvns draining into it can be demonstrated inferior to the right PA (Table 12.13). This view is good to demonstrate anatomy of the right PA and pulmonary venous drainage into the left atrium.

M. Color M-Mode Flow Propagation

Color M-mode imaging has been used to measure the early diastolic flow propagation velocity from the slope of the linear isovelocity contour to assess the rapid filling phase of diastole. The display shows time on the x axis and spatial distance, mean velocity of inflow, and the timing of this inflow on the y axis. This measure may be helpful in the evaluation of diastolic dysfunction. A normal propagation velocity is >50 to 55 cm/sec; propagation velocity of <45 cm/sec has been associated with impaired relaxation.²⁻⁵ To acquire this image, the M-mode cursor is aligned with the mitral inflow jet in the apical

view. The color M-mode box should be set to include the area from mitral annulus to the LV apex (Table 12.14). The color baseline should be moved toward the direction of flow to create aliasing in the forward flow direction so that the central highest velocity jet is blue. The slope is measured along the red first aliasing line of the signal in early diastole, which should have the same timing as the E wave. Measure from the mitral annulus to ≥ 4 cm into the left ventricle. Divide the distance into the left ventricle by time in seconds to obtain the slope in centimeters per second.^{2,3}

REFERENCES

1. Brown LM, Duffy CE, Mitchell C, Young L. A practical guide to pediatric coronary artery imaging with echocardiography. *J Am Soc Echocardiogr* 2015;28:379-91.
2. Brun P, Tribouilloy C, Duval A-M, Iserin L, Meguira A, Pelle G, et al. Left ventricular flow propagation during early filling is related to wall relaxation: a color M-mode Doppler analysis. *J Am Coll Cardiol* 1992;20:420-32.
3. Garcia MJ, Smedira NG, Greenberg NL, Main M, Firstenberg MS, Odabashian J, et al. Color M-mode Doppler flow propagation velocity is a preload insensitive index of left ventricular relaxation: animal and human validation. *J Am Coll Cardiol* 2000;35:201-8.
4. Stewart KC, Kumar R, Charonko JJ, Ohara T, Vlachos PP, Little WC. Evaluation of LV diastolic function from color M-mode echocardiography. *JACC Cardiovasc Imaging* 2011;4:37-46.
5. Takatsuji H, Mikami T, Urasawa K, Teranishi J-I, Onozuka H, Takagi C, et al. A new approach for evaluation of left ventricular diastolic function: spatial and temporal analysis of left ventricular filling flow propagation by color M-mode Doppler echocardiography. *J Am Coll Cardiol* 1996;27:365-71.